

Document Version

Final published version

Licence

CC BY-NC-ND

Citation (APA)

Willemsen, K., Nizak, R., Noordmans, H. J., Castelein, R. M., Weinans, H., & Kruyt, M. C. (2019). Challenges in the design and regulatory approval of 3D-printed surgical implants: a two-case series. *The Lancet Digital Health*, 1(4), e163-e171. [https://doi.org/10.1016/S2589-7500\(19\)30067-6](https://doi.org/10.1016/S2589-7500(19)30067-6)

Important note

To cite this publication, please use the final published version (if applicable).
Please check the document version above.

Copyright

In case the licence states "Dutch Copyright Act (Article 25fa)", this publication was made available Green Open Access via the TU Delft Institutional Repository pursuant to Dutch Copyright Act (Article 25fa, the Taverne amendment). This provision does not affect copyright ownership.
Unless copyright is transferred by contract or statute, it remains with the copyright holder.

Sharing and reuse

Other than for strictly personal use, it is not permitted to download, forward or distribute the text or part of it, without the consent of the author(s) and/or copyright holder(s), unless the work is under an open content license such as Creative Commons.

Takedown policy

Please contact us and provide details if you believe this document breaches copyrights.
We will remove access to the work immediately and investigate your claim.

Challenges in the design and regulatory approval of 3D-printed surgical implants: a two-case series



Koen Willemsen, Razmara Nizak, Herke Jan Noordmans, René M Castelein, Harrie Weinans, Moyo C Kruyt

Summary

Background Additive manufacturing or three-dimensional (3D) printing of metal implants can provide novel solutions for difficult-to-treat conditions, yet legislation concerning patient-specific implants complicates the implementation of these techniques in daily practice. In this Article, we share our acquired knowledge of the logistical and legal challenges associated with the use of patient-specific 3D-printed implants to treat spinal instabilities.

Methods Two patients with semiurgent cases of spinal instability presented to our hospital in the Netherlands. In case 1, severe kyphotic deformity of the thoracic spine due to neurofibromatosis type 1 had led to incomplete paralysis, and a strong metallic strut extending from C6 to T11 was deemed necessary to provide long-term anterior support. In case 2, the patient presented with progressive paralysis caused by cervicothoracic dissociation due to vanishing bone disease. As the C5–T1 vertebral bodies had mostly vanished, an implant spanning the anterior spine from C4 to T2 was required. Because of the complex and challenging nature of both cases, conventional approaches were deemed inadequate; instead, patient-specific implants were designed with use of CT scans and computer-aided design software, and 3D printed in titanium with direct metal printing. For each implant, to ensure patient safety, a comprehensive technical file (describing the clinical substantiation, technical and design considerations, risk analysis, manufacturing process, and labelling) was produced in collaboration with a university department certified for the development and manufacturing of medical devices. Because the implants were categorised as custom-made or personalised devices under the EU Medical Device Regulation, the usual procedures for review and approval of medical devices by a notified body were not required. Finite-element analyses, compression strength tests, and cadaveric experiments were also done to ensure the devices were safe to use.

Findings The planning, design, production, and insertion of the 3D-printed personalised implant took around 6 months in the first patient, but, given the experience from the first case, only took around 6 weeks in the second patient. In both patients, the surgeries went as planned and good positioning of each implant was confirmed. Both patients were discharged home within 1 week after the surgery. In the first patient, a fatigue fracture occurred in one of the conventional posterior fusion rods after 10 months, which we repaired, without any deformation of the spine or signs of failure of the personalised implant observed. No other adverse events occurred up to 25 months of follow-up in case 1 and 6 months of follow-up in case 2.

Interpretation Patient-specific treatment approaches incorporating 3D-printed implants can be helpful in carefully selected cases when conventional methods are not an option. Comprehensive and efficient interactions between medical engineers and physicians are essential to establish well designed frameworks to navigate the logistical and regulatory aspects of technology development to ensure the safety and legal validity of patient-specific treatments. The framework described here could encourage physicians to treat (once untreatable) patients with novel personalised techniques.

Funding Interreg VA Flanders—The Netherlands programme, Applied and Engineering Sciences research programme, the Netherlands Organisation for Scientific Research, and the Dutch Arthritis Foundation

Copyright © 2019 The Author(s). Published by Elsevier Ltd. This is an Open Access article under the CC BY-NC-ND 4.0 license.

Introduction

With advances in three-dimensional (3D) printing technology and the increasing availability of user-friendly software to design almost any shape, opportunities for customised surgical implants have emerged.^{1,2} We can now treat clinical conditions that could not previously be treated, and ineffective and demanding treatments for extreme conditions (such as tumour site reconstruction or extreme scoliosis) can be

substantially improved with use of patient-specific implants and cutting guides.^{3,4} As a consequence, more unique situations are amenable to unprecedented solutions than ever before.^{3,5,6}

Any new technology is—by definition—explorative, and guidelines and legislation for the use of such new techniques are imperative to mitigate the risk of mistakes.⁶ However, these regulations tend to be restrictive, and can even impede innovative and improved patient care. As a

Lancet Digital Health 2019; 1: e163–71

Published Online

July 23, 2019

[http://dx.doi.org/10.1016/S2589-7500\(19\)30067-6](http://dx.doi.org/10.1016/S2589-7500(19)30067-6)

S2589-7500(19)30067-6

See [Comment](#) page e149

Department of Orthopaedics (K Willemsen MD, R Nizak MSc, Prof R M Castelein MD, Prof H Weinans PhD, M C Kruyt MD) and Department of Medical Technology and Clinical Physics (H J Noordmans MSc), University Medical Centre Utrecht, Utrecht, Netherlands; and Department of Biomechanical Engineering, Delft University of Technology, Delft, Netherlands (Prof H Weinans)

Correspondence to: Mr Koen Willemsen, Department of Orthopaedics, University Medical Centre Utrecht, 3584 CX Utrecht, Netherlands k.willemsen-4@umcutrecht.nl

Research in context

Evidence before this study

Three-dimensional (3D) printing has the potential to provide personalised implant solutions for patients with difficult-to-treat conditions. However, the regulatory channels related to the application of these techniques are often unclear and bureaucratic. As a result, medical professionals often use suboptimal standardised techniques to treat patients with unique deformities. Based on a 2017 systematic review, we did an updated search of PubMed, Cochrane, and Embase (to Dec 1, 2018) using the following search terms: ((3D* or three*dimension* or 3* dimension*) adj1 (print* or model* or reprod* or manufactur* or templat* or mould or prototyp* or framework or represent*)).tw.; (additive* manufactur* or stereolithograph* or biomodel*).tw.; (computer* aided manufacturing or CAM or computer* aided engineer* or CAE or computer* aided design or computer-assisted design or CAD).tw.; (patient* adj1 (specific or adapt* or customi* or personali* or individuali*)).tw.; (implant* or prosthe* or insert* or model* or guid*).tw.; 9 adj1 10 (surg* adj1 (guid* or templ* or model*).tw.; 6 OR 7 OR 8 OR 11 OR 12. The 2017 systematic review identified only seven published articles on 3D-printed implants for the spine, four of which did not investigate the challenges of regulatory frameworks, whereas three only theorised about a new treatment method without introducing it into a clinical situation. Our updated search found no new articles. Therefore, further guidance on how to navigate these

regulatory frameworks is needed for physicians treating patients with unique conditions that require personalised 3D-printed solutions.

Added value of this study

In this report, we describe the challenges associated with the production of personalised 3D-printed implants in a hospital setting, from medical, organisational, and legal perspectives. With two case examples, we show the feasibility and relative ease of using 3D-implant solutions after a development workflow has been established. These examples may serve as guidance to physicians in similar situations to establish in-house development pathways and to create technical files describing the clinical substantiation, technical and design considerations, risk analysis, manufacturing process, and labelling for regulatory and legal purposes.

Implications of all the available evidence

Surgeons have been hesitant to treat patients with use of personalised 3D-printed implants, partly because of the challenges of navigating the applicable legislative regulations. However, patients with unique or difficult-to-treat defects can be effectively treated with such personalised approaches. These approaches will be facilitated if physicians familiarise themselves with setting up technical files and collaborate with mechanical engineers to establish workflows for the development of new 3D-printed personalised techniques.

result, surgeons are seeing a widening gap between the technical possibilities of personalised techniques and the extent to which these techniques can be realised. Furthermore, the pathways for navigating these regulations are often unclear and always bureaucratic,^{2,7,8} a scenario that is especially problematic in semiurgent situations that preclude a time-consuming approval procedure.² Consequently, surgeons often opt not for the best (ie, personalised) treatment, but for the more convenient, conventional approach.

An exemption from the usual approval procedure for the use of personalised implants can be obtained in an emergency or exceptional-use situation, when specific safety requirements are met.^{9,10} We believe that thorough and efficient interactions between medical engineers and physicians to establish well designed frameworks to navigate the logistical and regulatory aspects of personalised implant development are necessary. These frameworks can be locally administered and managed to obtain legal clearance for personalised implants in an optimal manner; only then can the possibilities be effectively exploited and the expected increase in personalised solutions accommodated.⁶ However, time and investment are required to understand the needs and language of physicians, engineers, government administrators, hospital management, and legal representatives to facilitate interactions between the relevant parties.

Previous studies of 3D-printed implants in the clinical setting have scarcely described the legal aspects and inherent decision-making dilemmas associated with these techniques,^{2,3,6} while studies that have investigated the legal aspects have not shown this application in the clinical setting.^{2,6,11} In this Article, we elaborate on the possibilities of 3D printing for complex spinal surgery as illustrated by two semiurgent cases for which we were able to create personalised solutions using 3D metal printing technology. We also describe the associated procedural workflow and regulatory framework that we had to navigate to achieve these solutions, as well as the advantages of thoroughly documenting these processes. We designed, manufactured, and implanted patient-specific, bone-integrating titanium implants for patients with severe destruction of the spine. As both cases were exceptional, no standard devices, procedures, or regulations were available; yet the surgical implantations had to be done within months in both cases to prevent paraplegia, during which time the spines were protected with an external orthosis. In terms of strength, invasiveness, fit, and efficacy, we consider these personalised treatments to have been far better than if we had attempted to use any conventional treatment options (such as placing posterior fusion rods anteriorly) in these unique cases. This report provides information that could encourage other surgeons with similar

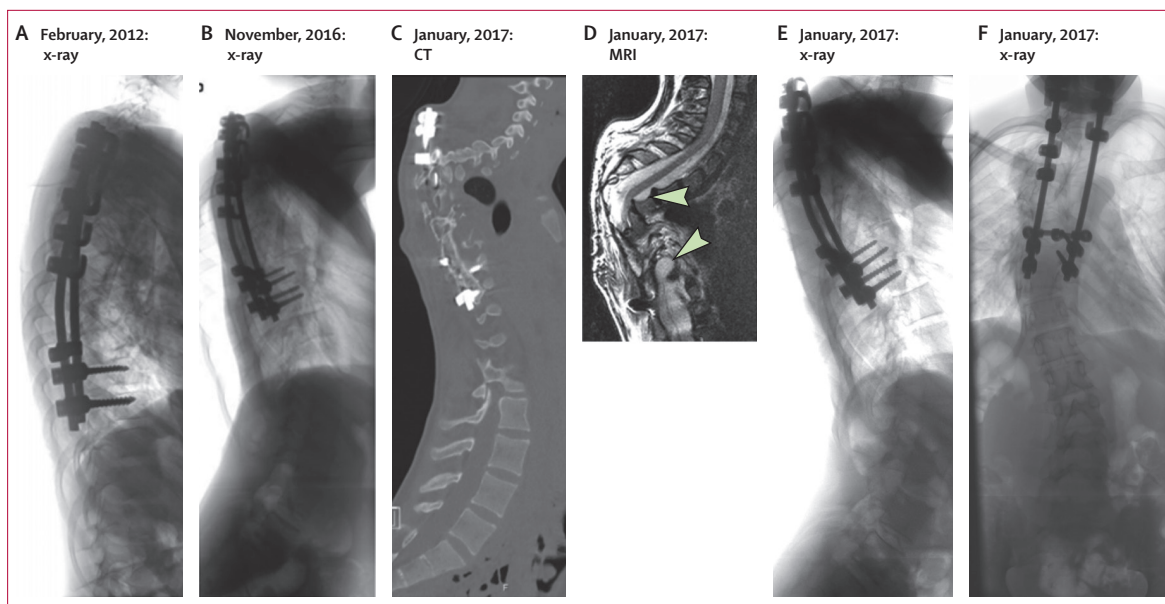


Figure 1: Pre-implantation imaging findings (case 1)

(A) Lateral x-ray in 2012, in which short segment fixation with rods for dystrophic scoliosis was visible. (B) Lateral x-ray (2016) showing considerable loss of alignment of the spine to the fixation rods with progressive kyphosis at T2–T3 due to proximal failure. (C) CT scan (2017) showing total collapse of the spine due to proximal failure, which was causing paralysis. (D) MRI (2017) showing the cord at risk, with destruction of the T3–T9 vertebrae due to dural ectasias (arrows). (E) Lateral x-ray (2017) showing extensive loss of alignment due to proximal failure. (F) Anterior-posterior x-ray (2017) showing considerable loss of alignment due to proximal failure.

unconventional cases to use patient-specific approaches and provides guidance on how to develop the necessary regulatory frameworks to ensure patient safety.

A video abstract is available online.

Methods

Case 1

Case background

A 16-year-old boy presented to the emergency department and subsequently to the department of orthopaedics of the University Medical Centre Utrecht (Utrecht, Netherlands) in January, 2017, with incomplete paralysis (American Spinal Injury Association impairment scale [AIS] grade C) due to severe kyphotic deformity of the thoracic spine resulting from neurofibromatosis type 1 (figure 1).¹² Neurofibromatosis type 1 is a single-gene disorder that affects around one in every 2500–3000 people, with scoliosis present in 10–26% of cases.^{12,13} Because of the development of dystrophic deformities, surgical management can be very challenging in these cases.¹⁴ Our patient had been treated for severe dystrophic scoliosis with a short posterior fusion (of vertebra T1–T10) 5 years earlier, in February, 2012. However, the proximal fixation progressively failed over a period of 5 years in the absence of sufficiently supportive vertebral bodies from T4 through T9, which were damaged by extensive and increasing dystrophic changes of the bone and dural ectasia (figure 1), eventually leading to incomplete paralysis and neurological symptoms. After urgent reduction with halo-gravity traction, the patient recovered neurologically

(AIS grade D), and the spine was aligned and stabilised with posterior fixation extending from C4 to L1 using lateral mass and pedicle screws, together with transition rods in January, 2017. Although this treatment was initially effective, the slender posterior fixation would not be mechanically sufficient for a long period and failure of the construct was deemed to be inevitable. Therefore, a more rigorous support at the anterior side of the spine was needed, which required a personalised approach. To allow time to develop a permanent solution, a temporary orthosis was used to protect the spine. Meanwhile, the patient was allowed to ambulate and to go home.

Anterior support

For provision of the necessary anterior support, structural bone grafting would be very difficult and unreliable because of the dystrophic nature of the neurofibromatosis and the large dural ectasias that would prevent bone integration.¹⁵ Standard anterior hardware would also be problematic: first because of the difficulty in shaping it properly in the presence of the bony deformation, and second because the hardware was not anticipated to match the mechanical demands of the spinal column over time. We concluded that a strong and solid metallic strut would be needed at the anterior side to assure reliable long-term support. Such a prosthesis had to be fixed and would ultimately need to integrate into the proximal and distal viable vertebral bone without interfering with vital structures such as the heart, lungs, and bronchi. The shape of the prosthesis had to be customised to ensure a perfect

See Online for video

	Requirements	Variables	Justification
Surgical approach			
Anatomical positioning of the implant	Must not interfere with anatomical structures in the cervical and thoracic spine	Size of implant, thickness of implant	Cadaveric trial surgery before implantation, experience of the surgical team, literature
Anatomical free space	Must allow positioning without great difficulties in the surgical approach	Drill guides, fitting guides for optimal placement on desired position	Cadaveric trial surgery before implantation, experience of the surgical team, literature
Implant specifications			
Material properties	Must not cause adverse tissue reaction	Material, hot isostatic pressing (metal stress-relieving treatment)	Literature
Implant strength	Must provide support for lifetime of patient, must provide axial compressive mechanical support	Size of implant, thickness of implant, weight of patient	Finite-element analysis, biomechanical compression test
Optimisation of bone-implant interface	Should have porous interface with bone to facilitate ingrowth	Pore-sizes, porosity, unit-cell structure	Literature
Screws	Must allow compressive fixation to the spine and provide rotational stability	Quantity, lengths, thickness, type, and trajectories of screws	Computer-aided design and three-dimensional analysis, finite-element analysis, literature
Alternatives			
Off-the-shelf implant and fixation rods	Should not be an equal or better treatment option than the personalised treatment	Size of spinal rods, osteosynthesis material	Literature, experience of the surgical team, biomechanical compression test

Table: Considerations in the risk analysis of personalised implants

fit with the surrounding intact vertebrae and to bridge the diseased bone, as well as to allow the least amount of mobilisation and dissection of the vital anatomy, especially around the structures of the mediastinum. The only way to achieve this was by designing a personalised implant with use of computer-aided design and 3D-print manufacturing. After extensive examination of the CT and MRI images, the surgical team decided that a personalised implant that spanned the anterior spine from C6 to T11 would be necessary to stabilise the spine. During a cadaveric trial surgery, we established that such an implant could be inserted through a standard right anterior approach to C6 and a separate right-sided thoracotomy through the bed of the eighth rib.

See Online for appendix

Regulatory framework

To allow the implantation of a personalised prosthesis, certain criteria needed to be met. The design and production process had to be lawful, using the proper regulatory channels, imaging requirements, design steps, and implant production. However, because of the semiurgent nature of the situation, these steps had to be taken quickly and simultaneously to allow prioritisation of our time for the design process and preparation of printing. This scenario precluded extensive procedures and formal tests of the implant.

For more on 3D Slicer see <https://www.slicer.org/>

According to the EU Medical Device Regulation, an orthopaedic implant is a medical device of class III, the highest risk class.⁷ Normally, a class III medical device should be provided with an extensive technical file that is reviewed by a notified body. This approval process usually takes years to complete and involves extensive clinical trials before approval is granted, which was impossible in this case. However, because the medical device for our patient was made specifically for one exceptional case, it

fell into a different category: custom-made or personalised devices.⁷ For a custom-made device, a technical file must be made in accordance with the procedures described in annex XIII of the Medical Device Regulation,⁷ although sufficient justification allows for deviation from the usual performance and safety demands. In the Netherlands, the technical file for a custom device does not have to be reviewed by a notified body. Therefore, we made a technical file in collaboration with the Department of Medical Technology and Clinical Physics of the University Medical Centre Utrecht (appendix pp 1–5). This department is ISO 13485 certified for the development and manufacturing of medical devices. The technical file described the clinical substantiation, all technical and design considerations (table), the risk analysis, manufacturing process, and labelling according to an Investigational Medicinal Device Dossier (appendix pp 1–5). We documented all the steps involved in creating this file.

Imaging

A conventional CT scan with a slice thickness of 1 mm (35 mAs, 120 kV) was used to create a dicom file that was segmented in 3D Slicer (version 4.5.0, revision 24735) to produce a 3D model of the bony structures. An initial threshold of 226 Hounsfield units was used for bone segmentation. The acquired model was exported in standard tessellation language (STL) format (a native file format for stereolithography software) for the design step.

Implant design

With regard to the size and geometry of the implant, we used a specific implant rationale to determine the design requirements (table). The implant had to be long enough to cover the destabilised portion of the spine, but small enough to allow a straightforward surgical approach. It

had to be thick enough to withstand the estimated forces of the spine for a lifetime, but must not interfere with anatomical structures. A prerequisite for a rapid design phase is a close collaboration with an (in-house) designer and mechanical engineer. The patient-specific implant was designed in close collaboration with the surgical team, using Blender software (version 2.78; Blender, Amsterdam, Netherlands).

The implant consisted of a solid cylindrical part stretching from C6 to T11 (figure 2). A proximal protrusion supported the inferior endplate of C6 and a distal protrusion rested on the superior endplate of T11. The protrusions were made partially porous at the bone-implant interface to allow bone ingrowth. A pore size of 500–600 μm with an overall porosity of 70% was used.^{16,17} For initial fixation of the implant and to accommodate bony integration, two proximal and distal screw holes were included in the implant; the preferred trajectory and optimal screw length were calculated and planned with use of computer-aided design software. To determine global strength, an in-silico finite-element analysis of the implant was done, which showed that the implant easily sustained axial stress of 500 N (appendix p 2)—far more than the mechanical forces exerted on the implant in the body. Finally, a biomechanical compression test was done on a supplementary prototype. This compression test showed that the implant had about ten-times higher stiffness and strength compared with a conventional 5.5-mm titanium rod (appendix p 2). To ensure an optimal fit and to check the implant, a 3D print of the spine and the prosthesis in plastic was made. After approval by the surgical team, the files of the final implant were sent in STL format to the implant manufacturer, together with two oversized implants (with an additional 2 mm or 4 mm added in the axial direction) to accommodate for slight size differences and unpredictable posture changes during surgery.¹⁸

Implant production

The implants were manufactured at a CE-certified 3D-printing facility, with ISO 9001:2008, ISO 13485:2003, and EN ISO 13485:2012 certificates for the scope of modelling and production of metal additively manufactured medical products (3D Systems, Leuven, Belgium). Printed products come with a manufacturer's declaration of conformity to ensure the required quality of the 3D-printing process (direct metal printing) and base materials (appendix p 1). The implants were 3D printed using medical grade titanium (Ti6Al4V ELI grade 23). The printing was done with a direct metal printing titanium 3D-printer DMP320 (3D Systems, Leuven, Belgium). Post-processing included hot isostatic pressing treatment,¹⁹ polishing, and screw hole finishing. Sterilisation of the implants was done at in-house sterilisation facility of the University Medical Centre Utrecht by manual cleaning, additional autoclave sterilisation, and sterile packaging.

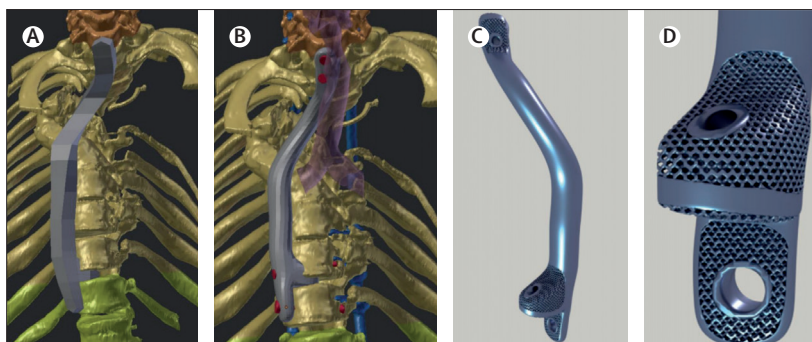


Figure 2: Design of personalised prosthesis (case 1)

(A) First step in the design process: a prototype that follows the mechanical axis near the spine, attaching to the last mechanically stable vertebrae in the cervical spine (C4–C5) and bridging the unstable part (C6–T11) to the first mechanically stable vertebra distal of the defect (T12). (B) Restructured prototype with addition of screw holes and their trajectories. (C) Final implant design (rendered picture). (D) Close-up view of the porous mesh structure to allow bone ingrowth, with distal screw holes.

Surgical procedure

After a standard right-sided anterior approach of the cervical spine to expose C6 and a mini thoracotomy through the bed of the eighth rib, with mobilisation of the right lung, a passage could be created with blunt finger dissection from proximal into the pleural cavity under endoscopic guidance. The docking sites were created by partial dissection of the intervertebral discs C6–C7 and T10–T11. Additional proximal and distal ends of the prosthesis were printed in polyamide to serve as a docking trial guide. The normal-sized implant had the best fit and was inserted from distal to proximal end. The fit was precise, and, after drilling and measuring, the pre-determined screws were inserted. Three 3.5-mm standard small fragment cancellous screws were used (two at the proximal side and one at the distal side), with an additional 6.5-mm fully threaded cancellous bone screw used at the distal side (DePuy Synthes, West Chester, PA, USA).

Case 2

Case background

The second patient, a 68-year-old woman with progressive paralysis (AIS grade C) due to a severe cervicothoracic dissociation, presented around 18 months after case 1, in October, 2018. The cervicothoracic dissociation was a consequence of vanishing bone disease,²⁰ which was diagnosed 20 years earlier and had resulted in multiple surgeries before the patient's condition was finally stabilised with a posterior C2–T5 fixation. Gorham's vanishing bone disease is a disease of unknown cause that is characterised by the destruction and absorption of bone, much like lytic metastasis but without oncological cells.²⁰ Eventually, in October, 2018, the posterior fixation failed proximally, possibly because of a minor trauma 2 months before. Because of the (partial) absence of the C5–T1 vertebral bodies, the cervical spine slowly deviated and collapsed, which caused neurological symptoms (figure 3). The patient was first treated with halo traction and posterior C2–T5 spinal fusion with allograft bone in

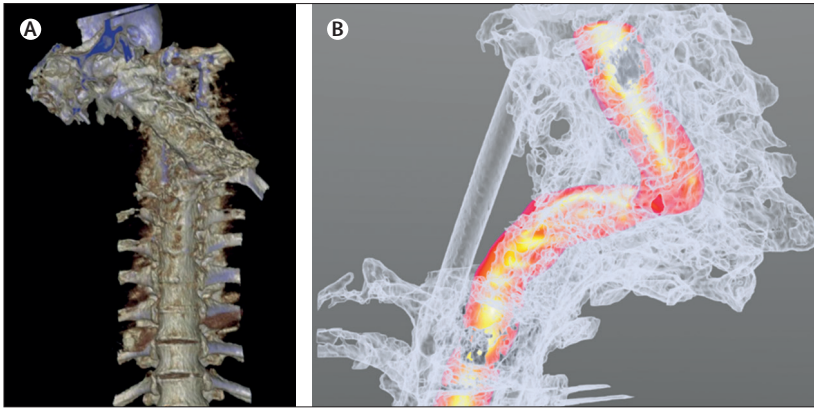


Figure 3: Pre-implantation imaging findings (case 2)

(A) CT reconstruction of severe cervicothoracic dislocation with deviation of the distal cervical spine to the left where it was resting on the first rib. The failed posterior fixation rods are shown in blue. (B) CT reconstruction with the spinal cord segmented (in red). The cord was curved into a syphon, with severe compression causing paralysis. White translucent structures shown are the bones and posterior fixation.

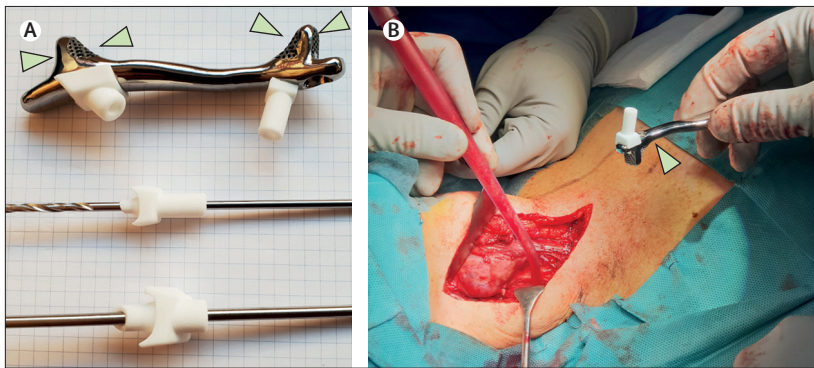


Figure 4: Prosthesis and surgery (case 2)

(A) Titanium prosthesis with polyamide drill guides for case 2. The prosthesis was made with porous ends (arrows) to allow bone integration. (B) Intraoperative image of the implant (arrow) before insertion; a right-sided standard anterior approach to the lower cervical spine was used (the patient's head is situated on the left side of the image).

October, 2018. She recovered remarkably well in the next weeks (to AIS grade E) and was discharged home. However, she needed to maintain the halo frame while the surgical team planned for anterior support because the C5–T1 vertebral bodies had mostly vanished.

Planning, design, and production of implant

We replicated the procedure followed in case 1 for the development of the anterior 3D-printed personalised prosthesis, including producing the technical file (appendix pp 1–5). Given the experience from the previous case, the team was better prepared, and we were able to complete the design, production, and regulatory procedures within weeks instead of months. We used commercially available software for segmentation (Mimics Medical 21.0; Materialise, Leuven, Belgium) and for implant design (3-Matic Medical 13.0; Materialise, Leuven, Belgium). An implant was designed that spanned the anterior spine from C4 to T2. Because of the smaller anatomical space, the implant was downsized compared

with case 1. The solid part of the design was approximately 10 mm in width, 5 mm in depth, and 88 mm in height, and curved in the axial plane to allow close positioning against the curved shape of the remaining anterior vertebral bodies. The proximal protrusion supported the inferior endplate of the lowest proximal healthy vertebra (C4) and the distal protrusion rested on the superior endplate of the T2 vertebra. As was done for case 1, the models of the spine and prosthesis were printed in plastic to verify shape and size. After approval from the surgical team, the personalised implant and one oversized version (with an additional 3 mm in height) were printed in titanium following the same production method as that for case 1.

Surgical procedure

The personalised prosthesis was inserted using a standard anterior approach to the lower cervical spine that gave excellent access to the fixation points at C4–C5 and T1–T2. Polyamide docking guides were again used. This time, the 3-mm oversized version of the implant was used with additional printed polyamide drill guides that facilitated precise predrilling of the screw holes (figure 4). At the proximal side, two 3.5-mm standard small fragment cancellous screws were used, and one 6.5-mm fully threaded cancellous bone screw (DePuy Synthes, West Chester, PA, USA) was used at the distal side.

Ethical approval

Both patients gave their consent for the procedures after being extensively informed about the first-in-human nature of these devices; patients were provided with information on the different treatment options, with a consent period, after which another appointment was made to answer additional questions before confirmation was acquired for these procedures. The patients also gave explicit consent for their cases and outcomes to be presented in this Article. Following Dutch legislation, a waiver for ethical review was granted by the Institutional Review Board of the University Medical Centre Utrecht (approval protocol number 19-371), as these treatments were not intended as clinical research.

Role of the funding source

The funders of the study had no role in study design, data collection, data analysis, data interpretation, or writing of the report. The corresponding author had full access to all the data in the study and had final responsibility for the decision to submit for publication.

Results

Case 1

After the consideration of multiple treatment approaches during the first weeks after the emergency treatment, the legal and regulatory possibilities were explored from week 3 onwards to initiate the patient-specific implant treatment plan. The official design process commenced

around week 8, with multiple design and five evaluation sessions with the surgical team. Two cadaveric sessions were planned to test the feasibility of the design, after which the implant was approved for production (around week 16). The design was sent for manufacturing at around week 18, with production and shipping taking 2 weeks. In week 20 the implant was delivered to the hospital facility for sterilisation and was made ready for the surgery.

The 3D-printed anterior implant was eventually inserted around 6 months after the emergency posterior stabilisation surgery. This procedure was uneventful and went as planned. Total surgery time after positioning of the patient was about 150 min, and blood loss was around 300 mL. Perioperatively, there were no complications, and postoperative CT confirmed good positioning of the prosthesis (figure 5). The patient recovered well and was discharged within 1 week. He was able to mobilise without further support, and returned to school 4 weeks after the surgery. Due to the patients' neurofibromatosis, frequent imaging and PET-CT scans were available up to 25 months post-surgery and showed good incorporation of the prosthesis, without signs of loosening of the implant. The patient's AIS grade improved from grade C to grade D after the emergency reduction and posterior refixation surgery, and subsequently showed gradual recovery over time (within AIS grade D), although some muscle weakness in his leg remained.

At 10 months post-surgery, a fatigue fracture occurred in the thin section of one of the conventional posterior fixation rods, without any deformation of the spine or signs of failure of the personalised anterior prosthesis. This fracture was probably the result of some remaining internal stress in the posterior system. Without the anterior stabilising implant, the spine may have collapsed further. In March, 2018, we repaired the rod with a small inline connector, and observed no other adverse events (figure 5). Frequent yearly follow-up and monitoring of the implant and function will be done as part of the monitoring planned for the patient's neurofibromatosis.

Case 2

In the first week after the emergency reduction and posterior refixation, a CT was done and the anatomy of the patient was segmented (including the spine, ribs, trachea, carotids, and oesophagus). This process was time consuming as the bone-tissue interface was not sharply defined because of the vanishing bone disease, and because the metallic posterior fixation induced a lot of beam hardening, necessitating intensive manual segmentation. In week 2, the implant was designed, with immediate in-house evaluation with the surgical team, after which the implant underwent two additional evaluation rounds. The implant was approved and physically printed at the beginning of week 4, and heat treated in week 5, followed by polishing and sterilisation before surgery.

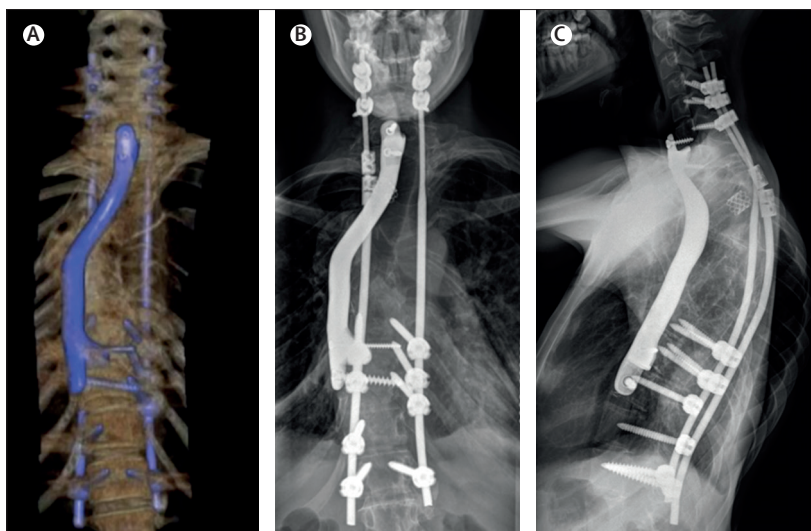


Figure 5: Post-implantation imaging findings (case 1)

(A) Three-dimensional reconstruction of the CT scan (anteroposterior view) of the spine after insertion of the personalised implant (shown in blue), showing good positioning of the implant. (B) Anteroposterior radiograph, 1.5 years after implantation, showing unaltered position of the prosthesis and no signs of failure. (C) Lateral radiograph at 1.5 years, showing the optimal anatomical position of the prosthesis.

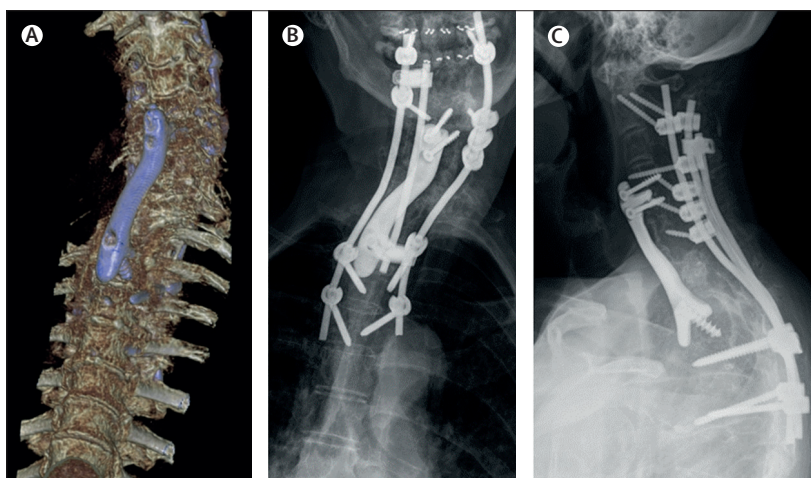


Figure 6: Post-implantation imaging findings (case 2)

(A) Three-dimensional reconstruction of CT scans (anteroposterior view) of the spine after insertion of the personalised implant, showing good positioning of the implant. Anteroposterior radiograph (B) and lateral radiograph (C) at 3 months after the surgery, showing unchanged position and no signs of failure of the implant.

The 3D-printed anterior implant was eventually inserted 6 weeks after the emergency posterior stabilisation surgery. The surgery went as planned and there were no perioperative complications. The duration of the surgery was about 120 min and blood loss was 200 mL. The patient did well after surgery. CT and x-ray confirmed correct positioning of the prosthesis and screws (figure 6), after which the halo frame could be removed. The patient was discharged home without restrictions within 1 week post-surgery. At 6 months post-surgery, the situation was unchanged and the patient was walking normally (AIS grade E).

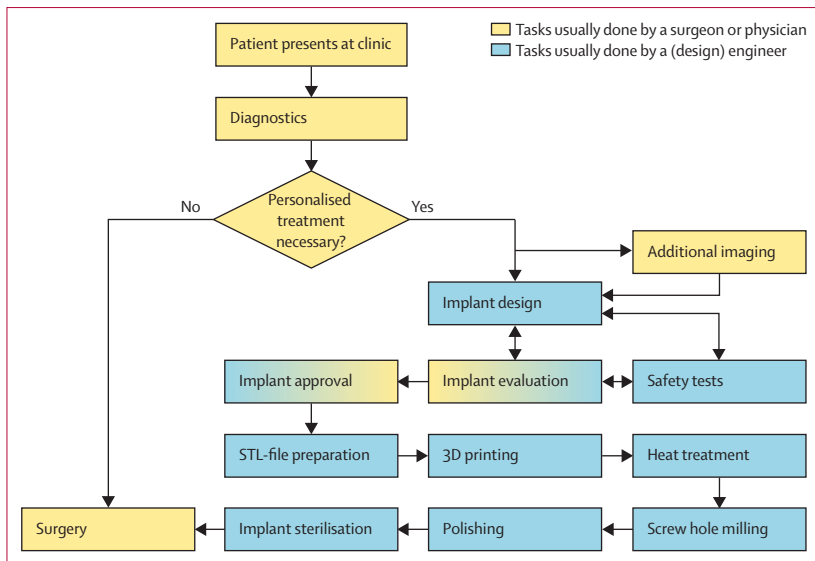


Figure 7: Workflow for development of personalised 3D implants

After a patient has been identified as needing personalised treatment, additional imaging is occasionally required to obtain higher-resolution images to allow optimal segmenting of the anatomical model. On this model, an implant is designed. After the design process, the implant needs to undergo formal (prototype) testing, after which a critical evaluation of the implant is made. Then, either the implant is approved for production or needs to be redesigned before undergoing another safety test and subsequent evaluation. The production requires STL-file preparation, which is uploaded to the 3D printer for physical 3D-printing. In our cases, we used hot isostatic pressing of the implant as a stress relieving treatment. After the heat treatment, the screw holes were finished, the implant was polished, and finally the implant was sterilised before surgery. 3D=three-dimensional. STL=standard tessellation language.

Discussion

The emergence of 3D imaging and direct metal printing techniques creates new possibilities for the surgical treatment of complex cases. Many papers have described the use of these technologies for preoperative planning²⁶ or for producing perioperative saw or drill guides.^{1,2,6} Additionally, commercial 3D-printed implants for spinal cages or acetabulum revision implants are available.² However, relatively few papers have described the use of patient-specific permanent spinal implants.^{6,21} One of the reasons that surgeons are hesitant to use the personalised 3D-printing technology is that there are many regulatory impediments to the implementation of this technology, resulting from the uncertain or extensive regulation of such implants, and the scarcity of in-house expertise for implant design and subsequent in-house production logistics.^{2,18}

In our cases, the process of ensuring compliance with the EU Medical Device Regulation was extensive but straightforward, requiring a procedural blueprint (figure 7) and a technical file with a detailed description of all steps and procedures (appendix pp 1–5). When this process has been done and documented well, it can be replicated and followed easily in subsequent cases, as shown in our two cases (in which the planning, design, approval, and production of the implants took 6 months for case 1 but only 6 weeks for case 2). The current EU Medical Device Directive annex XIII and the upcoming new Medical

Device Regulation leave enough flexibility for hospitals to organise their own development process for personalised implants. This process requires a team with surgeons and engineers, in close collaboration with the department of medical technology, which has extensive knowledge of implant legislation and legal matters. For such approaches to become more routine, ISO 13485 certification is advantageous as it allows for the production of medical devices, and the accompanying knowledge could help in the production of patient-specific medical devices. Furthermore, the regulatory procedures outlined in this Article are widely translatable in other EU countries, which are subject to the same regulations on medical devices. In the USA, the Food and Drug Administration also allows for a patient-centred approach: the special custom device exemption act allows use of custom-made devices for patients with special needs with a rare and unique pathology for which no conventional treatment is available.¹⁰

To fulfil all requirements from annex XIII of the EU Medical Device Regulation, all procedures involved in the design and production of the device must be registered for medical use. This requirement might be difficult to meet if using software packages, which are not always registered for medical use, although the EU Medical Device Regulation is not clear about whether the segmentation software and design software are medical devices themselves. In our cases, we had to guarantee that the shape and size of the 3D-printed implant would precisely fit to ensure no problems would occur during the operative procedure. Therefore, we thoroughly inspected and verified the size and shape of a plastic printed version of both the vertebrae and the implant. With respect to extensive mechanical tests, it was reasonable to presume that the implants would be stronger than conventional rods because of the increased diameter of the patient-specific implants; in fact, we maximised the size of the implants only on the basis of anatomical limitations. The finite-element analysis was done to confirm the hypothesis that the patient-specific implant would be stronger than a conventional rod. Because of time restrictions, the compression test was not done before the implantation for case 1. Nevertheless, a pro-forma compression test was done on one of the remaining oversized implants to confirm the safety and to act as a precedent for future cases, including case 2 (appendix p 2).

When the primary concern is the health of the patient, the surgeon can take responsibility for decisions that might deviate from the typical regulations, as long as they verify the safety of the treatment approach by providing argumentation and the rationale in the technical file for the implant. Whereas review by an ethics board is mandatory for experimental devices in clinical studies, it is not required for the application of new techniques and devices when patients are not participating in a clinical study.²² For such applications, the physician is responsible for ethical considerations,

and for providing extensive information to the patient and acquiring their consent.^{7,22}

To allow the advancing technical possibilities of custom medical devices to be realised in spite of the increasingly strict legislation on its use, close collaborations between physicians and engineers are essential, as are well documented technical files.¹⁸ In this regard, in-house knowledge on the design of 3D-printed implants is extremely helpful, and can even be a prerequisite in cases where time is limited. Face-to-face meetings among all parties involved in the planning and production of the device, as well as of generation of prototypes in-house, can speed up development.²³ The coordinator of the development workflow should preferably be either a physician who has received extensive training in design engineering, or a biomedical engineer who is trained to understand anatomy and surgical procedures.¹⁸ In many countries, medical technicians or design engineers are educated to design custom medical devices and guides for commercial companies. Incorporation of all the required services (engineering, legal, anatomy, and surgical) within one medical facility is of great value, especially for urgent cases.

When conventional methods are not an option, patient-specific treatment approaches can be helpful in carefully selected cases. A valid technical file with all necessary documents is essential to ensure the safety and legal validity of the approach. In this Article, we have provided a blueprint technical file based on two consecutive cases in which patient-specific implants were used with excellent results. We hope that this information can accelerate the introduction of personalised implants for other physicians. However, consideration must be given to local ethics and governmental legislation in other regions.

Contributors

All authors contributed to the study conception and design, data collection, data analysis, data interpretation, and writing of the report, and all approved the final version of the manuscript. KW, RN, HJN, HW provided administrative support. KW, RN, RMC, and MCK contributed to the provision of study materials and patient recruitment.

Declaration of interests

KW and HW have received research grants from the European Government through the Prosperos project and from the Dutch government through the Netherlands Organisation for Scientific Research (NWO; Applied and Engineering Sciences research programme, project number 15479) in relation to the submitted work. HW has also received a research grant from the Dutch Arthritis Foundation outside the submitted work. RMC and MCK have received unrestricted research grants from K2M outside of the submitted work. RN and HJN declare no competing interests.

Acknowledgments

The research leading to these results received partial funding from the Prosperos project, funded by the Interreg VA Flanders—The Netherlands programme (grant number 2014TC16RFCB046); the Dutch government through the Netherlands Organisation for Scientific Research (NWO; Applied and Engineering Sciences research programme, project number 15479); and from the Dutch Arthritis Foundation (grant number LLP-22).

References

1 Hoang D, Perrault D, Stevanovic M, Ghiassi A. Surgical applications of three-dimensional printing: a review of the current literature & how to get started. *Ann Transl Med* 2016; 4: 456.

- 2 Martelli N, Serrano C, van den Brink H, et al. Advantages and disadvantages of 3-dimensional printing in surgery: a systematic review. *Surgery* 2016; 159: 1485–500.
- 3 Xu N, Wei F, Liu X, et al. Reconstruction of the upper cervical spine using a personalized 3D-printed vertebral body in an adolescent with Ewing sarcoma. *Spine* 2016; 41: E50–54.
- 4 Pijpker PA, Kuijlen MA, Kraeima J, Faber C. Three-dimensional planning and use of individualized osteotomy-guiding templates for surgical correction of kyphoscoliosis: A technical case report. *World Neurosurg* 2018; 119: 113–17.
- 5 Parker SL, Wolinsky JP, Tufaro AP, Gokaslan ZL, Witham TF. Five-level cervical corpectomy for neurofibromatosis-associated spinal deformity: case report. *Eur Spine J* 2015; 24 (suppl 4): 544–50.
- 6 Wilcox B, Mobbs RJ, Wu AM, Phan K. Systematic review of 3D printing in spinal surgery: the current state of play. *J Spine Surg* 2017; 3: 433–43.
- 7 European Parliament, Council of the European Union. Regulation (EU) 2017/745 of the European Parliament and of the Council of 5 April 2017 on medical devices, amending Directive 2001/83/EC, Regulation (EC) no 178/2002 and Regulation (EC) no 1223/2009 and repealing Council Directives 90/385/EEC and 93/42/EEC. <https://www.emergogroup.com/sites/default/files/europe-medical-devices-regulation.pdf> (accessed Feb 21, 2019).
- 8 Phan K, Sgro A, Maharaj MM, D'Urso P, Mobbs RJ. Application of a 3D custom printed patient specific spinal implant for C1/2 arthrodesis. *J Spine Surg* 2016; 2: 314–18.
- 9 Bracci R, Maccaroni E, Cascinu S. Transient sunitinib resistance in gastrointestinal stromal tumors. *N Engl J Med* 2013; 368: 2042–43.
- 10 US Food and Drug Administration. Custom device exemption: guidance for industry and Food and Drug Administration staff. Sept 24, 2014. <https://www.fda.gov/media/89897/download> (accessed June 3, 2019).
- 11 de Beer N, Van Der Merwe A. Patient-specific intervertebral disc implants using rapid manufacturing technology. *Rapid Prototyping J* 2013; 19: 126–39.
- 12 Williams VC, Lucas J, Babcock MA, Gutmann DH, Korf B, Maria BL. Neurofibromatosis type 1 revisited. *Pediatrics* 2009; 123: 124–33.
- 13 Akbarnia BA, Gabriel KR, Beckman E, Chalk D. Prevalence of scoliosis in neurofibromatosis. *Spine* 1992; 17 (suppl): S244–48.
- 14 Duhem-Tonnelle V, Vinchon M, Defachelles AS, Cotten A, Dhellemmes P. Mature neuroblastic tumors with spinal cord compression: report of five pediatric cases. *Childs Nerv Syst* 2006; 22: 500–05.
- 15 Yilmaz K, Ozmen M, Goksan SB, Eskiyurt N. Bone mineral density in children with neurofibromatosis 1. *Acta Paediatr* 2007; 96: 1220–22.
- 16 Taniguchi N, Fujibayashi S, Takemoto M, et al. Effect of pore size on bone ingrowth into porous titanium implants fabricated by additive manufacturing: an in vivo experiment. *Mater Sci Eng C* 2016; 59: 690–701.
- 17 Van der Stok J, Van der Jagt OP, Amin Yavari S, et al. Selective laser melting-produced porous titanium scaffolds regenerate bone in critical size cortical bone defects. *J Orthop Res* 2013; 31: 792–99.
- 18 Choy WJ, Mobbs RJ, Wilcox B, Phan S, Phan K, Sutterlin CE 3rd. Reconstruction of thoracic spine using a personalized 3D-printed vertebral body in adolescent with T9 primary bone tumor. *World Neurosurg* 2017; 105: 1032.e13–17.
- 19 Benedetti M, Torresani E, Leoni M, et al. The effect of post-sintering treatments on the fatigue and biological behavior of Ti-6Al-4V ELI parts made by selective laser melting. *J Mech Behav Biomed Mater* 2017; 71: 295–306.
- 20 Nikolaou VS, Chytas D, Korres D, Efsthathopoulos N. Vanishing bone disease (Gorham-Stout syndrome): a review of a rare entity. *World J Orthop* 2014; 5: 694–98.
- 21 Choy WJ, Parr WCH, Phan K, Walsh WR, Mobbs RJ. 3-dimensional printing for anterior cervical surgery: a review. *J Spine Surg* 2018; 4: 757–69.
- 22 ACOG Committee on Ethics. ACOG Committee opinion no 352: innovative practice: ethical guidelines. *Obstet Gynecol* 2006; 108: 1589–95.
- 23 Krause FL, Ciesla M, Stiel C, Ulbrich A. Enhanced rapid prototyping for faster product development processes. *CIRP Ann* 1997; 46: 93–96.