

**Document Version**

Final published version

**Licence**

CC BY-ND

**Citation (APA)**

Amoozgar, H., Hosseini, H., Mohammadi, H., Fereidoonzhad, B., Eynbeygui, M., Arghavani, J., Zare, A., Mehdizadegan, N., Edraki, M. R., Naghshzan, A., Abedi, E., & Khorraminejad-Shirazi, M. (2026). Innovating Patent Ductus Arteriosus Closure: Preclinical Evaluation of the First Iranian-Developed Nitinol Occluder in a Sheep Model. *Iranian Journal of Medical Sciences*, 51(2), 118-125. <https://doi.org/10.30476/ijms.2025.107171.4151>

**Important note**

To cite this publication, please use the final published version (if applicable). Please check the document version above.

**Copyright**

In case the licence states "Dutch Copyright Act (Article 25fa)", this publication was made available Green Open Access via the TU Delft Institutional Repository pursuant to Dutch Copyright Act (Article 25fa, the Taverne amendment). This provision does not affect copyright ownership. Unless copyright is transferred by contract or statute, it remains with the copyright holder.

**Sharing and reuse**

Other than for strictly personal use, it is not permitted to download, forward or distribute the text or part of it, without the consent of the author(s) and/or copyright holder(s), unless the work is under an open content license such as Creative Commons.

**Takedown policy**

Please contact us and provide details if you believe this document breaches copyrights. We will remove access to the work immediately and investigate your claim.

# Innovating Patent Ductus Arteriosus Closure: Preclinical Evaluation of the First Iranian-Developed Nitinol Occluder in a Sheep Model

Hamid Amoozgar<sup>1</sup>, MD; Hossein Hosseini<sup>2</sup>, MD; Hamid Mohammadi<sup>3</sup>, MD; Behrooz Fereidoonzhad<sup>4</sup>, PhD; Mehdi Eynbeygui<sup>5</sup>, PhD; Jamal Arghavani<sup>5</sup>, PhD; Afshin Zare<sup>6</sup>, MD; Nima Mehdizadegan<sup>3</sup>, MD; Mohammad Reza Edraki<sup>3</sup>, MD; Amir Naghshzan<sup>3</sup>, MD; Elham Abedi<sup>7</sup>, PhD; Mohammadhossein Khorraminejad-Shirazi<sup>8,9,10</sup>, MD

<sup>1</sup>Neonatal Research Center, Department of Pediatrics, School of Medicine, Shiraz University of Medical Sciences, Shiraz, Iran;

<sup>2</sup>Student Research Committee, Shiraz University of Medical Sciences, Shiraz, Iran;

<sup>3</sup>Department of Pediatrics, School of Medicine, Shiraz University of Medical Sciences, Shiraz, Iran;

<sup>4</sup>Department of Biomechanical Engineering, Delft University of Technology, Delft, 2628 CD, Netherlands;

<sup>5</sup>Department of Mechanical Engineering, Sharif University of Technology, Tehran, Iran;

<sup>6</sup>Department of Surgery, Shiraz University of Medical Sciences, Shiraz, Iran;

<sup>7</sup>Hematology Research Center, Shiraz University of Medical Sciences, Shiraz, Iran;

<sup>8</sup>Zoonoses Research Center, Jahrom University of Medical Sciences, Jahrom, Iran;

<sup>9</sup>Department of Pathology, School of Medicine, Jahrom University of Medical Sciences, Jahrom, Iran;

<sup>10</sup>Department of Pathology, School of Medicine, Shiraz University of Medical Sciences, Shiraz, Iran

## Correspondence:

Hamid Mohammadi, MD;  
7<sup>th</sup> Floor, Deputy of Research and Technology, Central Building, Shiraz University of Medical Sciences, Zand Blvd., Postal Code: 7134814336, Shiraz, Iran  
Tel: +98 71 32122430

Email: Mohammadi219@gmail.com

Received: 20 May 2025

Revised: 28 June 2025

Accepted: 25 July 2025

## What's Known

- Existing Patent ductus arteriosus (PDA) occluders face challenges such as high cost, limited accessibility, and anatomical variability, particularly in resource-limited settings.

## What's New

- This study introduces the first Iranian-developed nitinol-based PDA occluder, demonstrating safety, biocompatibility, and structural durability in a preclinical sheep model, offering a cost-effective alternative.

## Abstract

**Background:** Patent ductus arteriosus (PDA) is a congenital defect characterized by abnormal blood flow between the aorta and pulmonary artery. Existing closure devices, such as the Amplatzer Duct Occluder (ADO), face challenges with affordability, biocompatibility, and anatomical adaptability. This study evaluates the safety and feasibility of a novel nitinol-based PDA occluder, the first developed sample in Iran, designed to enhance biocompatibility, reduce thrombogenicity, and improve durability.

**Methods:** This preclinical study was conducted in 2024 at the Large Animal Research Laboratory, Shiraz University of Medical Sciences, Shiraz, Iran. The occluder was fabricated from custom-made nitinol wires braided into a 72-wire conical mesh, ensuring flexibility and durability. Deployment was tested in a sheep model via femoral and pulmonary artery access. Post-procedure evaluations included angiography, clinical monitoring, and histopathological analyses to assess tissue integration, thrombogenicity, and biocompatibility.

**Results:** The device was successfully deployed in two target sites with stable positioning and no procedural complications. Angiographic imaging confirmed vessel patency, even in an artery with a size mismatch. The animal exhibited no adverse outcomes, maintaining normal pulses and activity over a three-month follow-up. Post-mortem analysis revealed secure device placement without migration, perforation, or aneurysm. Histopathological findings demonstrated mild inflammation, neointimal formation, and re-endothelialization, with no significant thrombus or granuloma, indicating excellent biocompatibility.

**Conclusion:** This study provides preliminary evidence supporting the feasibility, safety, and biocompatibility of the Iranian-developed PDA occluder. These findings suggest the device may serve as a viable, cost-effective alternative for PDA closure, addressing device shortages and advancing regional medical technology.

Please cite this article as: Amoozgar H, Hosseini H, Mohammadi H, Fereidoonzhad B, Eynbeygui M, Arghavani J, Zare A, Mehdizadegan N, Edraki MR, Naghshzan A, Abedi E, Khorraminejad-Shirazi MH. Innovating Patent Ductus Arteriosus Closure: Preclinical Evaluation of the First Iranian-Developed Nitinol Occluder in a Sheep Model. Iran J Med Sci. 2026;51(2):118-125. doi: 10.30476/ijms.2025.107171.4151.

**Keywords** • Patent ductus arteriosus • Nitinol • Thrombosis • Biocompatible materials • Sheep

## Introduction

Patent ductus arteriosus (PDA) is a congenital cardiac defect in which the ductus arteriosus fails to close after birth, resulting in abnormal blood flow between the aorta and the pulmonary artery.

Transcatheter closure of PDA with devices such as the Amplatzer Duct Occluder (ADO) has revolutionized treatment, reducing the need for open-heart surgery. However, challenges remain in addressing diverse anatomical variations, ensuring long-term biocompatibility, and maintaining affordability, particularly in low- and middle-income countries.<sup>1,2</sup>

Advancements in PDA occluder designs, including the Amplatzer Duct Occluder II (ADO II) and Amplatzer Duct Occluder II Additional Size (ADO II AS), have introduced nitinol-based structures, multi-layered mesh configurations, and low-profile delivery systems, enhancing flexibility, occlusive performance, and accessibility for smaller patients, including neonates.<sup>3,4</sup> These devices demonstrate high closure success rates, exceeding 98%, and low complication rates.<sup>4</sup> Despite these advancements, clinical studies have reported limitations such as residual shunts, device embolization, and transient arrhythmias, emphasizing the need for further innovation in device materials and deployment mechanisms.<sup>5-8</sup>

In Iran, accessibility and affordability of patent ductus arteriosus (PDA) occluders remain a major issue. Although international devices such as the Amplatzer Duct Occluder are widely used, their high cost and limited availability hinder access for many patients. Existing device designs often incorporate nonwoven Dacron components, which, while aiding occlusion, have been associated with increased thrombogenicity.<sup>9</sup> There is therefore a need for cost-effective, biocompatible alternatives that meet international standards for safety and performance while addressing these limitations.

Preclinical animal models are essential for evaluating new PDA occluders, as they allow assessment of deployment mechanics, vascular compatibility, and long-term tissue integration under controlled conditions.<sup>10</sup> The sheep cardiovascular system closely resembles that of humans, making it a valuable model for studying device performance, thromboresistance, and histopathological outcomes in arterial environments.<sup>7,8</sup>

Therefore, this study aimed to evaluate the feasibility, deployment precision, and biocompatibility of a newly developed Iranian nitinol-based PDA occluder, designed without Dacron augmentation, in a preclinical sheep model.

## Materials and Methods

This preclinical study was conducted in 2024 at the Large Animal Research Laboratory, Shiraz University of Medical Sciences, Shiraz, Iran. The study protocol was reviewed and approved by

the Institutional Animal Care and Use Committee (IACUC) of Shiraz University of Medical Sciences (code. IR.SUMS.AEC.1404.026) and performed in accordance with international ethical guidelines for animal research, including the NIH Guide for the Care and Use of Laboratory Animals.<sup>11</sup> The manuscript is reported according to the ARRIVE guidelines for reporting animal research.<sup>12</sup>

### *Device Design and Manufacturing*

The Iranian PDA occluder was developed to enhance safety, efficacy, and durability in clinical use. Fabricated from nitinol, a biocompatible alloy with shape-memory properties, the occluder was engineered for both flexibility and strength. The device's structure was created using a custom braiding machine that interlaces 72 nitinol wires into a uniform mesh. While the technical specifics of this machine are proprietary, it harmonizes multiple headers to synchronously interlace the wires around a cylindrical core. The mesh was subsequently heat-treated to form a conical occluder, ensuring optimal structural integrity and functionality.<sup>1,2</sup> Figure 1 illustrates the components and structure of the Iranian PDA occluder (or Amplatzer).

### *Braiding and Assembly*


The device components were assembled with precision, including a laser-welded head and a threaded end piece designed to interface with the current available delivery system. The occluder was prepared without nonwoven Dacron in this iteration to evaluate its thrombogenicity in an arterial environment, a critical consideration for long-term biocompatibility and safety.<sup>3</sup> Extensive preclinical tests ensured compatibility with various delivery catheters, confirmed the device's ability to expand effectively, and verified detachment mechanics in simulated vascular environments.<sup>4</sup>

### *Preclinical Testing*

The device underwent rigorous preclinical testing to assess the mechanical properties, including device expansion, detachment under controlled conditions, and its overall performance in a vascular environment. These assessments were designed to ensure reproducibility and safe deployment.<sup>13</sup>

### *Sterilization and Preparation*

For implantation, four occluders (6×8 mm) were selected, thoroughly cleaned, sterilized with ethylene oxide, and loaded into six French delivery catheter systems for minimally invasive deployment, following standardized practices for device sterilization and preparation.<sup>1</sup>



**Figure 1:** The fabrication and structure of the Iranian PDA occluder are illustrated. (A) Braiding of 72 nitinol wires using a custom braiding machine to form the uniform mesh. (B and C) The heat-treated conical occluder, showing its shape and threading for attachment to the delivery system. (D) Assembled device with a laser-welded head and threaded end piece. (E) Close-up of the laser-welded connection ensuring structural integrity. (F) Final assembled occluder device ready for deployment. The occluder was manufactured without Dacron to evaluate thrombogenicity and biocompatibility in preclinical testing.

#### Animal Model and Housing

One adult female sheep (*Ovis aries*), weighing 40 Kg, was selected for this study. Sheep's cardiovascular anatomy resembles that of humans, making it suitable for evaluating occluder deployment and function.<sup>3</sup> The animal was housed in a controlled environment with regulated temperature, humidity, and access to a standard diet and water, ensuring well-being throughout the study.

The use of a single animal was primarily aimed at feasibility testing and evaluating device performance in an initial pilot model. While this model limits the statistical power and generalizability of findings, it serves as an important preliminary step to inform larger studies.

#### Surgical Procedure

**Preoperative Care:** The sheep was fasted for 8 hours before the procedure. Anesthesia was induced using midazolam, ketamine, and propofol, with additional sedatives and analgesics administered as required for comfort and pain management.<sup>3</sup> The surgical site was prepared under sterile conditions to reduce the

risk of infection.

**Vascular Access and Deployment:** Vascular access was achieved via the right femoral vein and artery using the Seldinger technique.<sup>14</sup> Heparin (100 units/Kg) was administered intravenously to prevent thrombosis during the procedure.<sup>15</sup> Under fluoroscopic guidance, a 6 French delivery catheter was advanced through the femoral vein to the left pulmonary artery. The occluder was deployed at the target site, where it expanded and secured itself in position. A second device was deployed in the right femoral artery to assess arterial thrombogenicity. Post-deployment angiography confirmed optimal device placement and vessel patency.<sup>16, 17</sup>

**Post-Operative Monitoring:** Following the procedure, the delivery catheter was removed, and hemostasis was achieved at the vascular access sites. The sheep was closely monitored during the recovery phase, with appropriate post-operative care, including wound management and monitoring for complications such as bleeding, infection, or respiratory distress.<sup>7, 8</sup>

#### Outcome Measures

The primary outcome measures included

successful device deployment, absence of procedural complications (e.g., dislodgement, thrombosis, vascular injury), and the absence of immediate adverse events.<sup>7</sup> Over the follow-up period of 3 months, the animal was regularly monitored for signs of complications, including bleeding, infection, respiratory distress, or vascular issues, and underwent imaging to assess the device's position and tissue integration.<sup>8</sup>

At the end of the study, healthy farm animals without complications are routinely sacrificed according to standard Islamic slaughter procedures, in accordance with institutional and national regulations for farm animal research. If complications arise that preclude routine sacrifice, humane euthanasia with intravenous sodium pentobarbital (100 mg/Kg) is performed under IACUC-approved protocols.<sup>18</sup> In the present case, the animal survived without complications and was sacrificed by routine farm practice. A post-mortem examination was performed to evaluate device placement, vessel patency, and histological tissue responses, including thrombosis or other complications.

#### *Tissue Collection and Histopathological Evaluation*

Tissue samples were collected from the arterial wall at the occluder implantation site, adjacent proximal and distal vessel segments, and surrounding perivascular tissues for histopathological analysis. These samples were fixed in formalin, embedded in paraffin, sectioned, and stained with hematoxylin and eosin to assess general tissue response. Additional special stains for thrombi were used to evaluate thrombogenicity at the occluder interface. The histopathological analysis was conducted by independent pathologists to minimize bias. Criteria for evaluating biocompatibility and thrombogenicity included the extent of tissue integration, reendothelialization, and any signs of thrombus formation or inflammatory response.<sup>3</sup>

#### *Statistical Analysis*

Descriptive statistics were used to summarize procedural outcomes, post-procedural complications, and histopathological findings. Qualitative assessments of device deployment, positioning, and tissue responses were documented. Additionally, the long-term success of the occlusion and any adverse events were recorded and analyzed, informing future studies and device refinement.

## Results

### *Procedural Outcomes*

The Iranian occluder device was

successfully deployed in both positions, with stable positioning within the deployment site confirmed by post-deployment angiography. The deployment procedure was straightforward, with the device demonstrating ease of manipulation and the ability to be released and repositioned without complications. Despite the occluder being slightly larger than the recommended size for the femoral artery diameter, no immediate procedural complications were observed, such as device dislodgement, vascular aneurysm, or rupture. After deployment, dye injection confirmed patency of the artery, with no obstructions observed after 10 min. These findings suggest that the device is safe for use in arterial closure procedures, even when slightly mismatched to the femoral artery size.

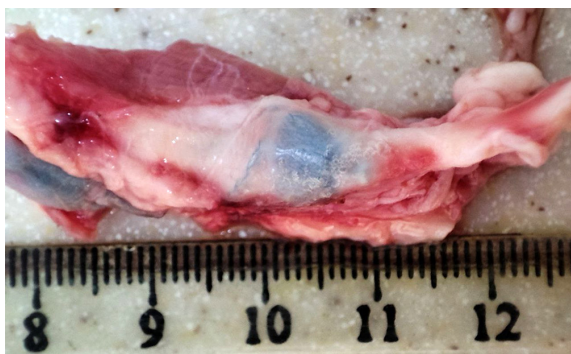### *Post-procedural Follow-up*

Throughout the 3-month post-procedural follow-up, the animal was evaluated weekly for distal pulses in the right leg, the site of one device implantation. All evaluations showed patent pulses, with no signs of claudication. Additionally, during the 3-month follow-up, the animals did not exhibit any signs of respiratory distress, bleeding, or infection, indicating that they recovered well from the procedure. The animal maintained normal appetite and activity levels, suggesting a favorable post-procedural recovery. Distal pulses in the right leg remained patent throughout the follow-up, and no migration of the device to the distal portion of the artery was observed. These findings demonstrate the durability and stability of the device in the arterial site over a prolonged period.

### *Post-mortem Examination*

Post-mortem examination confirmed that both occluders remained securely positioned: one in the left pulmonary artery and one in the right femoral artery, with no evidence of migration or dislodgement. A gross examination of the right femoral artery revealed no signs of vascular perforation, erosion, aneurysm formation, or significant thrombus at or distal to the device location. These findings were consistent with the absence of device-related vascular complications, further supporting the device's safety. The occluder was well-embedded in the artery, with no signs of movement, despite the initial mismatch to the femoral artery size (figure 2).

Microscopic examination of tissue sections stained with hematoxylin and eosin demonstrated mild to moderate inflammatory cell infiltration surrounding the occluder, predominantly consisting of lymphocytes, plasma cells, and macrophages.



**Figure 2:** The gross pathological image illustrates the Iranian occluder securely positioned within the femoral artery, even though it was oversized for this vessel. The device appears stable and embedded without causing thrombosis in the proximal and distal parts of the artery.

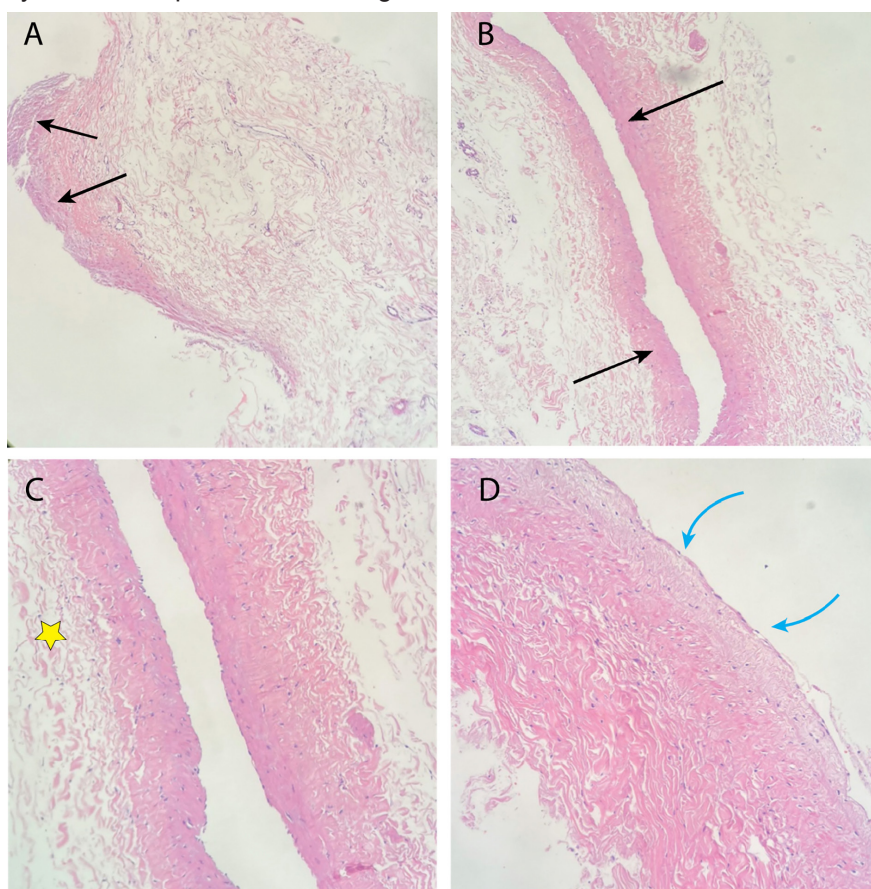
This inflammatory response is a typical reaction to a foreign implant and is consistent with normal healing processes. Additionally, varying degrees of neointimal formation and reendothelialization were observed around the occluder mesh, indicating the initiation of tissue incorporation. Importantly, no significant thrombus formation, vessel wall injury, or granuloma formation was observed in any tissue sample. These findings

support the biocompatibility of the Iranian occluder device, confirming its potential for safe and effective arterial closure (figure 3).

These pathological findings collectively highlight the favorable biocompatibility and safety profile of the Iranian occluder device, as well as its potential for long-term, durable closure of the ductus arteriosus.

## Discussion

This pilot study presents a groundbreaking evaluation of the Iranian-made PDA occluder device, representing a significant step toward addressing medical device shortages and fostering new facilities for multidisciplinary research between clinicians and engineers. The nitinol mesh structure of the device was designed to provide flexibility, durability, and biocompatibility, targeting the safety and efficacy benchmarks established by international standards. The findings from this pilot study suggest that the Iranian occluder compares favorably with other devices in the literature in terms of deployment success, biocompatibility, and long-term safety.



**Figure 3:** Histopathological evaluation of the specimen with hematoxylin and eosin staining. Panels A and B (40× and 100× magnifications) demonstrate the formation of a neointimal layer (black arrows) surrounding the occluder, indicative of tissue remodeling and re-endothelialization. Panel C (200×) shows only mild inflammatory infiltrates (yellow asterisk), while Panel D (400×) illustrates the smooth neointimal surface (blue arrow), together supporting acceptable biocompatibility and integration of the device.

The successful deployment of the Iranian occluder without immediate complications aligns with the procedural success rates observed in studies evaluating devices such as the Amplatzer Duct Occluder.<sup>2, 10</sup> Similar to findings by Boehm and colleagues,<sup>14</sup> the absence of dislodgement, vascular rupture, or aneurysm despite size mismatches between the device and arterial diameter supports the mechanical reliability of the occluder and the flexibility of nitinol in accommodating variances in vascular anatomy. This contrasts with studies reporting complications such as femoral artery transection during PDA closure, underscoring the need for precise device sizing and operator expertise.<sup>1, 9</sup>

The angiographic confirmation of artery patency post-deployment highlights the device's non-thrombogenicity. Similar outcomes have been reported in other studies, emphasizing the need for angiographic assessments in evaluating device safety during preclinical stages.<sup>4, 11, 14</sup> However, additional large-scale studies with diverse vascular anatomies are warranted to generalize these findings.

The sustained patency of distal pulses over a three-month follow-up reflects the stability and biocompatibility of the Iranian device. The absence of thrombogenic responses suggests that excluding Dacron from the Iranian device reduces thrombus formation, a hypothesis supported by comparisons with other nitinol-based devices.<sup>1, 2</sup> These results are consistent with the findings of Rodríguez and colleagues,<sup>10</sup> who observed no vascular access complications or device migration in preterm infants undergoing PDA occlusion with the ADO-II-AS.

The biocompatibility of the device is further evidenced by histopathological findings. Mild to moderate inflammatory responses and the presence of neointimal formation and reendothelialization around the mesh are consistent with the natural process of foreign body incorporation observed in similar studies.<sup>3</sup> Notably, no thrombus or granuloma formation was detected, corroborating findings by Santhanam and others, who reported minimal thrombotic complications in peri-membranous ventricular septal defect closures.<sup>5</sup> This contrasts with Iskander and colleagues, who highlighted device-related thrombi in atrial septal defect closures, likely attributable to differences in implantation site and procedural techniques.<sup>8</sup>

When compared to commercially available devices, the Iranian occluder demonstrates potentially comparable safety and biocompatibility, with the added advantage of local production and cost-effectiveness. For instance, studies

on similar devices, such as the Amplatzer Duct Occluder, highlight high occlusion rates and minimal adverse events.<sup>16, 17</sup> The Iranian device's nitinol mesh design likely contributes to its favorable profile, as nitinol has been shown to enhance flexibility and reduce thrombogenicity compared to devices incorporating Dacron or other foreign materials.<sup>2, 17</sup>

However, certain inconsistencies require attention. While studies such as those by Liu and colleagues reported minor complications, including residual shunting and arrhythmias, during transcatheter peri-membranous ventricular septal defect closure;<sup>6</sup> these complications were not observed in the present study due to the incomplete device profile, including the lack of Dacron patch incorporation.

As the first of its kind developed in Iran, this device could significantly impact the availability and affordability of PDA closure devices. The findings from this pilot study suggest that the Iranian PDA occluder device is a viable alternative for addressing vascular closure needs, particularly in low-resource settings with limited access to imported medical technologies. Its flexible design and biocompatibility position it as a potentially safer option for minimizing complications. However, larger preclinical studies with more animal models and eventual clinical trials are necessary to substantiate these results and explore the device's applicability across different patient populations.

Future investigations should emphasize refining deployment techniques, optimizing device sizing protocols, and evaluating long-term outcomes, particularly in pediatric and low-weight patients, who are at higher risk for procedural complications.<sup>8, 9</sup> By addressing these aspects, the Iranian occluder could emerge as a significant domestic advancement, offering an effective solution for PDA closure worldwide.

## Conclusion

This study provides strong preliminary evidence of the technical feasibility, manufacturing capability, safety, efficacy, and biocompatibility of the Iranian PDA occluder. While further research and clinical trials are needed, the findings indicate that this device could be a viable, cost-effective alternative for PDA closure, manufactured locally. Its development marks progress toward self-reliance in medical technology, potentially addressing global device shortages. With refinement, it could become a valuable addition to interventional device closure.

## Acknowledgment

We extend sincere gratitude to the Department of Animal Science, School of Agriculture, Shiraz University, and the Pars Veterinary Clinic for their cooperation in providing facilities for angiographic intervention and animal care. We deeply appreciate the National Institute for Medical Research Development (NIMAD) for supporting this research and addressing device availability limitations in Iran. Finally, we acknowledge Dr. Younes Ghasemi, former Vice Chancellor of Shiraz University of Medical Sciences, whose contributions were instrumental. This study was supported by the National Institute for Medical Research Development (NIMAD) as part of an initiative to address medical device shortages (grant no. 972638).

## Authors' Contribution

H.M. contributed to the conception and design of the study, supervision, animal model investigation, and critical manuscript revision. H.H. contributed to data acquisition, literature review, drafting and revising the manuscript, and animal investigation. N.M, H.A., M.R.E., and A.N. contributed to clinical conceptualization, interpretation of findings, and critical manuscript review; H.A. and M.R.E. also contributed to animal model investigations. B.F., M.E, and J.A. contributed to device design and fabrication, technical input, and manuscript revision. A.Z. contributed to surgical assistance and procedural optimization. E.A. contributed to hematological evaluation and biocompatibility assessment. M.K.S. contributed to histopathological analysis and interpretation. All authors reviewed the manuscript critically for important intellectual content, approved the final version to be published, and agreed to be accountable for all aspects of the work in ensuring accuracy and integrity.

## Declaration of AI

The authors declare that no AI tools were used in the preparation of this manuscript.

**Conflict of Interest:** None declared.

## References

1 Bass JL, Wilson N. Transcatheter occlusion of the patent ductus arteriosus in infants: experimental testing of a new Amplatzer device. *Catheter Cardiovasc Interv.* 2014;83:250-5. doi: 10.1002/ccd.22931. PubMed PMID: 24446324.

- 2 Bruckheimer E, Steiner K, Barak-Corren Y, Slanovic L, Levinzon M, Lowenthal A, et al. The Amplatzer duct occluder (ADOII) and Piccolo devices for patent ductus arteriosus closure: a large single institution series. *Front Cardiovasc Med.* 2023;10:1158227. doi: 10.3389/fcvm.2023.1158227. PubMed PMID: 37215550; PubMed Central PMCID: PMC10193946.
- 3 Jalal Z, Seguela PE, Baruteau AE, Benoist D, Bernus O, Villemain O, et al. Role of animal models for percutaneous atrial septal defect closure. *J Thorac Dis.* 2018;10:S2966-S74. doi: 10.21037/jtd.2018.07.119. PubMed PMID: 30305957; PubMed Central PMCID: PMC6174152.
- 4 Yildiz K, Narin N, Oksuz S, Ozdemir R, Pamukcu O, Baykan A, et al. Safety and efficacy of Amplatzer duct occluder II and konar-MF VSD occluder in the closure of perimembranous ventricular septal defects in children weighing less than 10 kg. *Front Cardiovasc Med.* 2023;10:1255808. doi: 10.3389/fcvm.2023.1255808. PubMed PMID: 38094116; PubMed Central PMCID: PMC10716692.
- 5 Santhanam H, Yang L, Chen Z, Tai BC, Rajgor DD, Quek SC. A meta-analysis of transcatheter device closure of perimembranous ventricular septal defect. *Int J Cardiol.* 2018;254:75-83. doi: 10.1016/j.ijcard.2017.12.011. PubMed PMID: 29273241.
- 6 Liu J, Wang Z, Gao L, Tan HL, Zheng Q, Zhang ML. A Large Institutional Study on Outcomes and Complications after Transcatheter Closure of a Perimembranous-Type Ventricular Septal Defect in 890 Cases. *Acta Cardiol Sin.* 2013;29:271-6. PubMed PMID: 27122716; PubMed Central PMCID: PMC4804839.
- 7 Cen H, Peng B, Li J, Chen S, Sun P. Efficacy and safety of the Amplatzer Duct Occluder II for ventricular septal defect closure: a meta-analysis. *Kardiol Pol.* 2021;79:401-9. doi: 10.33963/KP.15762. PubMed PMID: 33506659.
- 8 Iskander B, Anwer F, Oliveri F, Fotios K, Panday P, Arcia Franchini AP, et al. Amplatzer Patent Foramen Ovale Occluder Device-Related Complications. *Cureus.* 2022;14:e23756. doi: 10.7759/cureus.23756. PubMed PMID: 35402119; PubMed Central PMCID: PMC8980243.
- 9 Fiszler R, Chojnicki M, Szkutnik M, Haponiuk I, Chodor B, Bialkowski J. Are the AMPLATZER Duct Occluder II Additional Sizes devices

- dedicated only for smaller children? *Euro-Intervention*. 2017;12:2100-3. doi: 10.4244/EIJ-D-15-00238. PubMed PMID: 27867138.
- 10 Rodriguez Ogando A, Ballesteros Tejerizo F, Blanco Bravo D, Sanchez Luna M, Zunzunegui Martinez JL. Transcatheter Occlusion of Patent Ductus Arteriosus in Preterm Infants Weighing Less Than 2 kg With the Amplatzer Duct Occluder II Additional Sizes Device. *Rev Esp Cardiol (Engl Ed)*. 2018;71:865-6. doi: 10.1016/j.rec.2017.08.014. PubMed PMID: 28916428.
  - 11 National Research Council (US) Committee for the Update of the Guide for the Care and Use of Laboratory Animals. *Guide for the Care and Use of Laboratory Animals*. 8th ed. Washington: National Academies Press; 2011.
  - 12 Percie du Sert N, Hurst V, Ahluwalia A, Alam S, Avey MT, Baker M, et al. The ARRIVE guidelines 2.0: Updated guidelines for reporting animal research. *PLoS Biol*. 2020;18:e3000410. doi: 10.1371/journal.pbio.3000410. PubMed PMID: 32663219; PubMed Central PMCID: PMC7360023
  - 13 Nour A, Abdelrazik Y, Huessin S, Kamel H. Safety and efficacy of percutaneous patent ductus arteriosus closure: a multicenter Egyptian experience. *Egypt Heart J*. 2022;74:14. doi: 10.1186/s43044-022-00251-3. PubMed PMID: 35244792; PubMed Central PMCID: PMC8897530.
  - 14 Portillo E, Mackin A, Hendrix PK, Boyle C, Chrestman L. Comparison of the modified Seldinger and through-the-needle jugular catheter placement techniques in the dog. *J Vet Emerg Crit Care (San Antonio)*. 2006;16:88-95. doi: 10.1111/j.1476-4431.2006.00147.x.
  - 15 Sideris G, Magkoutis N, Voicu S, Kang C, Bonneau M, Yannopoulos D, et al. A novel experimental thrombotic myocardial infarction and primary angioplasty model in swine. *EuroIntervention*. 2019;14:e1843-e51. doi: 10.4244/EIJ-D-17-00763. PubMed PMID: 29901442.
  - 16 Boehm W, Emmel M, Sreeram N. The Amplatzer duct occluder for PDA closure: indications, technique of implantation and clinical outcome. *Images Paediatr Cardiol*. 2007;9:16-26. PubMed PMID: 22368670; PubMed Central PMCID: PMC3232577.
  - 17 Pepeta L, Dippenaar A. Ductal closure using the Amplatzer duct occluder type two: experience in Port Elizabeth hospital complex, South Africa: cardiovascular topic. *Cardiovasc J Afr*. 2013;24:202-7. doi: 10.5830/CVJA-2013-033. PubMed PMID: 23812377; PubMed Central PMCID: PMC4986386.
  - 18 Kiani AK, Pheby D, Henahan G, Brown R, Sieving P, Sykora P, et al. Ethical considerations regarding animal experimentation. *J Prev Med Hyg*. 2022;63:E255-E66. doi: 10.15167/2421-4248/jpmh2022.63.2S3.2768. PubMed PMID: 36479489; PubMed Central PMCID: PMC9710398.