

## General Aspects of Fractures in Children

Bilo, Rob A.C.; Loeve, Arjo A.J.; Robben, Simon G.F.; Van Rijn, Rick R.

**DOI**

[10.1007/978-3-031-12041-1\\_2](https://doi.org/10.1007/978-3-031-12041-1_2)

**Publication date**

2023

**Document Version**

Final published version

**Published in**

Forensic Aspects of Paediatric Fractures

**Citation (APA)**

Bilo, R. A. C., Loeve, A. A. J., Robben, S. G. F., & Van Rijn, R. R. (2023). General Aspects of Fractures in Children. In R. A. C. Bilo, S. G. F. Robben, & R. R. van Rijn (Eds.), *Forensic Aspects of Paediatric Fractures: Differentiating Accidental Trauma from Child Abuse, Second Edition* (pp. 23-43). Springer. [https://doi.org/10.1007/978-3-031-12041-1\\_2](https://doi.org/10.1007/978-3-031-12041-1_2)

**Important note**

To cite this publication, please use the final published version (if applicable). Please check the document version above.

**Copyright**

Other than for strictly personal use, it is not permitted to download, forward or distribute the text or part of it, without the consent of the author(s) and/or copyright holder(s), unless the work is under an open content license such as Creative Commons.

**Takedown policy**

Please contact us and provide details if you believe this document breaches copyrights. We will remove access to the work immediately and investigate your claim.

***Green Open Access added to TU Delft Institutional Repository***

***'You share, we take care!' - Taverne project***

**<https://www.openaccess.nl/en/you-share-we-take-care>**

Otherwise as indicated in the copyright section: the publisher is the copyright holder of this work and the author uses the Dutch legislation to make this work public.



# General Aspects of Fractures in Children

# 2

Rob A. C. Biló, Arjo A. J. Loeve, Simon G. F. Robben,  
and Rick R. van Rijn

## Contents

2.1	<b>Introduction</b> .....	24
2.1.1	Definition .....	24
2.1.2	Epidemiology .....	24
2.2	<b>Diagnosis and Differential Diagnosis of Fractures in Children</b> .....	25
2.2.1	Clinical Presentation .....	25
2.2.2	Differential Diagnosis .....	25
2.3	<b>Fracture or Mimic</b> .....	26
2.4	<b>Fracture Description</b> .....	27
2.4.1	Anatomic Location and Type of Bone .....	27
2.4.2	Type of Fracture and Direction of Fracture Lines .....	30
2.4.3	Position and Relationship of the Fracture Components .....	30
2.4.4	Complications .....	30
2.5	<b>Cause of Fractures (Mechanism)</b> .....	31
2.5.1	General Aspects .....	31
2.5.2	High-Energy Trauma .....	31
2.5.3	Low-Energy Trauma .....	32
2.6	<b>Manner of Fractures (Circumstances)</b> .....	35
2.6.1	Intrauterine Fractures .....	35
2.6.2	Fractures During Birth: Birth Trauma .....	36

---

R. A. C. Biló  
Veilig Thuis Rotterdam Rijnmond (Center for the Reporting of  
Child Abuse, Domestic Violence and Elder Abuse),  
Rotterdam, The Netherlands

A. A. J. Loeve  
Department of Biomechanical Engineering, Faculty of Mechanical,  
Maritime and Materials Engineering, Delft University of  
Technology, Delft, The Netherlands  
e-mail: [A.J.Loeve@tudelft.nl](mailto:A.J.Loeve@tudelft.nl)

S. G. F. Robben (✉)  
Department of Radiology, Maastricht University Medical Center,  
Maastricht, The Netherlands  
e-mail: [s.robbe@mumc.nl](mailto:s.robbe@mumc.nl)

R. R. van Rijn  
Department of Radiology and Nuclear Medicine, Amsterdam  
UMC, University of Amsterdam, Amsterdam, The Netherlands

Department of Forensic Medicine, Netherlands Forensic Institute,  
The Hague, The Netherlands  
e-mail: [r.r.vanrijn@amsterdamumc.nl](mailto:r.r.vanrijn@amsterdamumc.nl)

2.6.3 Fractures After Birth: Accidental Circumstances .....	37
2.6.4 Fractures After Birth: Non-Accidental Circumstances .....	37
2.6.5 Fractures After Birth: Other Circumstances .....	40
<b>References</b> .....	40

## 2.1 Introduction

### 2.1.1 Definition

A fracture is a partial or complete disruption of the continuity of bone or cartilage, due to mechanical forces exceeding the strength of the bone or cartilage to withstand these forces.

### 2.1.2 Epidemiology

Fractures regularly occur in children. Most fractures in children are due to accidental trauma [1].

Landin did several large studies in the Malmö region in Sweden [2, 3]. In 1983, he reported on a retrospective study regarding 8642 children. It concerned all fractures in children treated over a period of 30 years in Malmö (between 1950 and 1979). In 1997 he added more recent data to his original study. In the Malmö region, the chance to sustain a fracture between birth and the age of 16 was in the reported period 42% for boys and 27% for girls. The overall annual incidence of fractures in children turned out to be 2.1% (2.6 for boys; 1.7 for girls). This percentage did not differ significantly from the reported incidence of the annual incidence of 1.6% reported for boys and girls in an English study of children with fractures treated clinically as well as in outpatient clinics [4].

In the period after the reports of Landin in 1983 and 1997 and Worlock in 1986, the incidence of paediatric fractures, reported by other authors, only slightly fluctuated, depending on the studied population and the country of origin (Table 2.1) [4, 6, 9].

Rennie et al. found that the incidence of fractures increased with age [5]. They also found that most fractures were due to falls from a bed (height <1 m). Most fractures

were found in the upper extremity. Fractures in the lower limbs were mostly due to a trauma in which the limb was twisted and to road traffic accidents.

Hedström et al. found that the most common fracture site was the distal forearm [6]. The most common type of trauma mechanism was a fall on the outstretched hand (FOOSH). The peak incidence occurred at 11–12 years in girls and at 13–14 years in boys, with a male-to-female incidence ratio of 2 to 1. They also found variations in mechanisms and activities with age, and over time. They noticed a slight increase of the incidence in the period between 1998 and 2007 compared to the first period they evaluated (1993 to 1997). According to them this partly could be due to changes in children's activity patterns over time.

Mäyränpää et al. noticed an increase in the incidence of fractures in the period between 1967 and 1983, but also noticed a significant decrease between 1983 and 2005 [7]. This decrease was largest in children between the ages of 10 and 13 years and most marked in hand and foot fractures. However, the incidence of forearm and upper arm fractures increased significantly (about one-third) in this period. Fractures were mainly due to falls when running or walking or falls from heights under 1.5 m. Fracture incidence peaked at 10 years in girls and 14 years in boys.

In 2010, Mathison and Agrawal reported an increasing incidence of paediatric fractures despite public health measures to prevent childhood injuries [9]. The incidence increased with age with a peak between the age of 12 and 15 years. Boys were over 50% more likely to sustain a fracture than girls. They concluded that traditional play activities continued to be the prevalent cause for fractures, but that there also was an increase in new sport and recreational activities, e.g. skateboarding, that carried significant fracture risk. They saw a higher incidence during the summer season. Fractures were seen more often in children from families with a low socioeconomic status, obese children, and children with risk taking behaviour. Furthermore it was seen in children with decreased bone density, eating disorders and inadequate nutrition, with chronic corticosteroid or performance-enhancing drugs use, and in smoking minors. Trauma from high risk taking behaviour, e.g. from sports, including extreme sports, accounted for a majority of fractures in middle and high school age children. Popular recreational play devices such as heelys, scooters, and all-terrain vehicles were highly associated with fractures [9, 10].

**Table 2.1** Incidence of fractures in children

Author	Incidence/100	Male vs female	Age
Worlock and Stower [4]	1.6		
Landin [3]	2.1	2.6 vs 1.7	<16 years of age
Rennie et al. [5]	2.0	61 vs 39%	
Hedström et al. [6]	2.0	1.5 vs 1	<20 years of age
Mäyränpää et al. [7]	1.6	63 vs 37%	<16 years of age
Naranje et al. [8]	1.8		<18 years of age

Naranje et al. tried to identify the most common paediatric fractures per 1000 children between the ages of 0 and 19 years in 2010 by using 2010 National Electronic Injury Surveillance System (NEISS) database and 2010 US Census information [8]. They found that children between 10 and 14 years of age had the highest risk of sustaining fractures. Forearm fractures were the most common, accounting for 17.8% of all fractures, whereas finger and wrist fractures were the second and third most common, respectively. Finger and hand fractures were most common for age groups 10 to 14 and 15 to 19 years, respectively.

Wilkins and Aroojis stated that 6.8% of the fractures sustained by children in the first 16 years of their life is severe enough to require admittance to hospital [11]. Slightly less than 20% of children who visit a hospital for sustained injuries appear to have sustained a fracture. According to Naranje et al., most paediatric fractures can be treated on outpatient basis, with only 1 of 18 fractures requiring hospitalization or observation [8].

In conclusion, the incidence of fractures in childhood is high, approximately 2%. Boys fracture their bones twice as often as girls. The incidence increases with age with a peak incidence between 10 and 15 years. The distal arm is most frequently affected and FOOSH is the most common trauma mechanism.

## 2.2 Diagnosis and Differential Diagnosis of Fractures in Children

### 2.2.1 Clinical Presentation

Fractures, irrespective of the circumstances under which the fractures were sustained, are usually identified based on the medical history and the presence of clinical manifestations such as pain, swelling, inability to move, and abnormal alignment. For a fracture without clinical manifestations generally no medical help will be sought.

Pain will occur at the same time as the fracture. Swelling may occur immediately after the fracture occurred. Pain will increase when the afflicted body part is moved. This may be an active movement, such as when the child wants to move the afflicted body part, or a passive movement, e.g. when a parent or caretaker wants to change the diaper or bathes the child.

When there is no dislocation of the fracture parts, the acute inflammatory symptoms around the fracture may be limited to just a few days. Up to toddler age, children may be pain-free within a few days after the fracture has been sustained, whereas in older children and adults this may take much longer [12].

In young children, however, fractures frequently have an occult course [13, 14]. There are various reasons for this phe-

nomenon. Non-mobile children have a limited movement pattern, which makes it harder to notice when a child does not move a body part over a longer or shorter period of time or whether its movement is somewhat restricted. Secondly, the periosteum acts as a splint, resulting in a lesser chance of mutual movement of the separated bone parts. And finally, if the fracture was inflicted, seeking medical advice is often postponed for a few days. During that period there may even be spontaneous recovery to such an extent that it is or seems no longer necessary to seek medical advice.

### 2.2.2 Differential Diagnosis

The differential diagnosis of fractures in a forensic paediatric evaluation demands differentiating between

1. Fractures or mimics of fractures (Sect. 2.4; Chap. 14).
2. Different causes of fractures (Sect. 2.5; Chaps. 5–14) in skeletally immature or mature patients and in normal or weakened bone.
3. Different circumstances under which the fracture can be sustained (Sect. 2.6; Chaps. 5–14).

Doctors involved in a forensic paediatric evaluation (e.g. paediatricians, radiologists, and forensic doctors) should work together in a structured manner. Table 2.2 provides an example of a structured approach. Doctors should follow, as far as possible and reasonable, all steps, before concluding what caused the fracture in a specific child and under which circumstances this fracture was sustained. Central to this diagnostic process is taking a detailed clinical history. Furthermore, the age and level of development of the child should be taken into consideration: the younger the child, the more limited his/her mobility, and the more probable that an injury, e.g. a fracture, was inflicted. In the differentiation, known trauma mechanisms and biomechanical aspects of fractures should also be taken into consideration (this chapter; Chaps. 5–12). Other factors that should be taken into account are the distribution of the fractures over the skeleton and the context in which the fractures were sustained (Chaps. 5–14).

During childhood, fractures are usually the result of accidents [15]. The differential diagnosis, apart from falls or accidents, witnessed by an independent person, or periosteal reactions that resemble a healing fracture, can be very comprehensive (Chaps. 5–14). One should realize that a suspicion of an inflicted fracture in a child also suggests the use of severe violence, probably by (one of) the parents. This emphasizes the importance of a structured approach, which should lead to a correct identification and prevent overhasty conclusions.

In this process, the (paediatric) radiologist is eminently important for an adequate diagnosis and protection of the

**Table 2.2** Evaluation of fractures in young children

Step 1	Take a detailed clinical history Diagnostic procedures, focused on the initial signs and symptoms (medical history, radiology, laboratory)
Step 2	Fracture or mimic (Sect. 2.3)
If the diagnosis is a fracture	
Step 3	Describe the individual fracture(s) (Sect. 2.4)
	<ul style="list-style-type: none"> <li>Anatomic location, type of fractured bone, affected part of the bone.</li> <li>Type of fracture and direction of the fracture line</li> <li>Position and relationship of fracture components</li> <li>Complications</li> </ul>
	Describe all fractures
	<ul style="list-style-type: none"> <li>Number.</li> <li>Distribution: <ul style="list-style-type: none"> <li>Axial and/or peripheral</li> <li>Symmetric or asymmetric</li> <li>Weight-bearing/non-weight-bearing parts of the skeleton</li> </ul> </li> <li>Age of the fractures and in case of multiple fractures differences in age/recent versus old (known and unknown) fractures</li> </ul>
Step 4	Describe the skeleton
	<ul style="list-style-type: none"> <li>Configuration of the bones and the whole skeleton, i.e. the presence of underlying metabolic diseases and/or skeletal dysplasias</li> <li>Findings suggesting skeletal lesions, like normal variants or ‘wormian bones’</li> </ul>
Step 5	Describe the child
	<ul style="list-style-type: none"> <li>Age and level of development</li> <li>Known/suspected underlying pathology</li> <li>Other injuries</li> </ul>
Step 6	Test the plausibility of the clinical history by using evidence-based scientific data concerning
	<ul style="list-style-type: none"> <li>Probability of accidental versus non-accidental circumstances related to the age and level of mobility of the child</li> <li>Fracture biomechanics</li> </ul>

child at the moment that it is suspected that the fracture(s) was (were) inflicted. The radiologist is expected to be able to [16, 17]:

- Perform a correct radiological examination, according to the international standards.
- Detect the radiological abnormalities that are suggestive of (inflicted) fractures in both suspect and non-suspect cases.
- Distinguish between radiological abnormalities that are suspect for (inflicted) fractures and normal variants or disorders, simulating a healing or healed fracture.
- Reconstruct theoretically the causing trauma mechanism, based on the characteristics of the fracture and the known mechanisms, described in the medical literature.
- Evaluate whether the fracture and the known underlying trauma mechanisms are compatible with the given statements of the child and/or parents regarding its origin.

- Summarize which findings in the radiological evaluation could indicate accidental or non-accidental circumstances.
- Date fractures, based on the findings on imaging, within the limitations of scientific knowledge.

To fulfill these expectations it is essential that the radiologist who evaluates the characteristics of paediatric fracture(s) has sufficient knowledge of the clinical history of the patient, of known causing trauma mechanisms, and of paediatric radiology.

### 2.3 Fracture or Mimic

If clinical symptoms or findings on imaging are suggestive for a fracture, the first step in the (differential) diagnostic process, after taking a detailed clinical history and appropriate diagnostic procedures, is to exclude that the finding is a true mimic. A true mimic is defined here as a normal variant or a disorder, which appears on imaging simulates as a fresh or a healing or healed fracture [18]. In Table 2.3 an overview is given of normal variants and disorders that mimic healing or healed fractures. In Chap. 14, these normal variants and disorders are discussed extensively.

Some of the mimics, like Raine syndrome (OMIM #259775, osteosclerotic bone dysplasia), McCune-Albright syndrome (OMIM #174800, fibrous dysplasia), Alagille syndrome (OMIM #118450, arteriohepatic dysplasia) and metabolic disorders like the mucopolysaccharidoses may show findings on imaging that are similar to those showing in healing or healed fractures. Others may show findings suggestive of recent fractures, e.g. spondylometaphyseal dysplasia corner fracture type (OMIM #184255). Children with these syndromes/disorders however nowadays often are already recognized at birth or early in infancy because of the presence of significant additional findings.

If a real fracture is found in a child with a disorder with an increased risk for fractures due to weakening of the bone (e.g. osteogenesis imperfecta), this disorder should not be considered to be a true mimic of a fracture. There is a real fracture and a fracture is always caused by trauma in which the loading of the bone exceeded the maximum load-bearing capacity (Sect. 2.5.3.4: fatigue fractures in weakened bone). Finding a fracture in a child with a disorder does not automatically indicate under which circumstances the fracture was sustained (Sect. 2.6). Fractures due to weakening of bone can be considered to be a mimic of inflicted fracturing in child abuse, because an adequate clinical history may be lacking.

Some disorders can be seen as true mimics, while also showing an increased risk of fractures. Menkes syndrome

**Table 2.3** Normal variants and medical conditions, mimicking (healing) fractures (not all inclusive) (see also Chap. 14)

	Examples
Normal variants	<ul style="list-style-type: none"> <li>• Subperiosteal new bone formation (shaft of femur, tibia and humerus, usually bilateral) in normal, healthy neonates and infants</li> <li>• Normal metaphyseal variants</li> <li>• Accessory growth centres</li> <li>• Unfused growth plate of the shoulder</li> <li>• Unfused apophysis of the fifth metatarsal</li> <li>• Accessory skull sutures</li> <li>• Accessory ossicles</li> <li>• Vascular/nutrient lines</li> </ul>
Haematological disorders, malignancies, and benign tumours	<ul style="list-style-type: none"> <li>• Sickle cell anaemia</li> <li>• Leukaemia</li> <li>• Ewing sarcoma</li> <li>• Osteoid osteoma and osteoblastoma</li> </ul>
Congenital/genetic disorders	<ul style="list-style-type: none"> <li>• Caffey's disease (infantile cortical hyperostosis) (OMIM # 114000)</li> <li>• Bone dysplasias</li> <li>• Metabolic disorders, e.g. mucopolysaccharidoses</li> <li>• Alagille syndrome (OMIM #118450)</li> <li>• Copper deficiency/Menkes syndrome (OMIM #309400)</li> <li>• Metaphyseal chondroplasia (type Schmid) (OMIM #156500)</li> <li>• Spondylometaphyseal dysplasia ('corner fracture type') (OMIM #184255)</li> </ul>
Infections or healing/healed infections	<ul style="list-style-type: none"> <li>• Osteomyelitis and chronic relapsing multifocal osteomyelitis</li> <li>• Congenital syphilis</li> <li>• Septic arthritis</li> </ul>
Vitamin deficiencies	<ul style="list-style-type: none"> <li>• Vitamin D deficiency (rickets)</li> <li>• Vitamin C deficiency (scurvy).</li> </ul>
Vitamin overdose	<ul style="list-style-type: none"> <li>• Hypervitaminosis A/vitamin A toxicity</li> <li>• Vitamin E therapy</li> </ul>
Growth disturbance	<ul style="list-style-type: none"> <li>• Harris lines: lines of increased bone density due to growth retardation or cessation (Sect. 5.12.2)</li> </ul>
Medical intervention	<ul style="list-style-type: none"> <li>• Prostaglandin E</li> <li>• Intra-osseous vascular access needles</li> </ul>

(OMIM #309400) and copper deficiency, for example can be seen as true mimics, because of the presence of metaphyseal spurs, suggesting classical metaphyseal lesions and periosteal reactions, which appear as healing fractures. In both disorders however there is also an increased risk of fracturing, because of weakening of the bone (osteoporosis) due to disturbances in bone metabolism and for that reason may mimic inflicted fractures.

## 2.4 Fracture Description

As already stated in Sect. 2.1.1, a fracture is the partial or complete disruption of the continuity of a bone, due to mechanical forces exceeding the strength of the bone or cartilage to withstand these forces.

Fractures have different appearances on imaging:

- Most fractures are visible as a lucent (black) line on radiographs or CT.
- When a fracture is impacted, due to compressional forces, the overlapping fragments can produce a dense (white) line on imaging. In the spine these compressional forces result in a loss of height of vertebral bodies (compression fracture).
- Incomplete fractures may present as small interruption of the smooth continuous cortical curve of bones, like buckles or acute angulations.
- Avulsion fractures cause separation of small bony fragments from the metaphysis, or increased distance and/or malalignment of secondary ossification centres from the metaphysis.
- Fractures through a growth plate result in malalignment between epiphysis and metaphysis, with or without variations in thickness of the growth plate.
- Occult fractures are fractures that are present but not visible on imaging. This can occur when the fracture is small and the X-ray beam is not parallel to the fracture plane, or when the fracture is in exactly the same plane as the CT slice. Occult fractures usually become apparent on imaging 2 weeks later because of subperiosteal new bone formation and widening of the fracture line due to reparative bone resorption.

Fractures are described according to [19–23]:

- The anatomic location, the type of fractured bone, and the affected part of the bone.
- The type of fracture and the direction of fracture lines.
- The position and the relationship of the fracture parts.
- The complications.

### 2.4.1 Anatomic Location and Type of Bone

The first step in the description of a fracture is the correct anatomic identification of the fractured bone, the type of the fractured bone and, related to the type of bone, the part of bone that is affected.

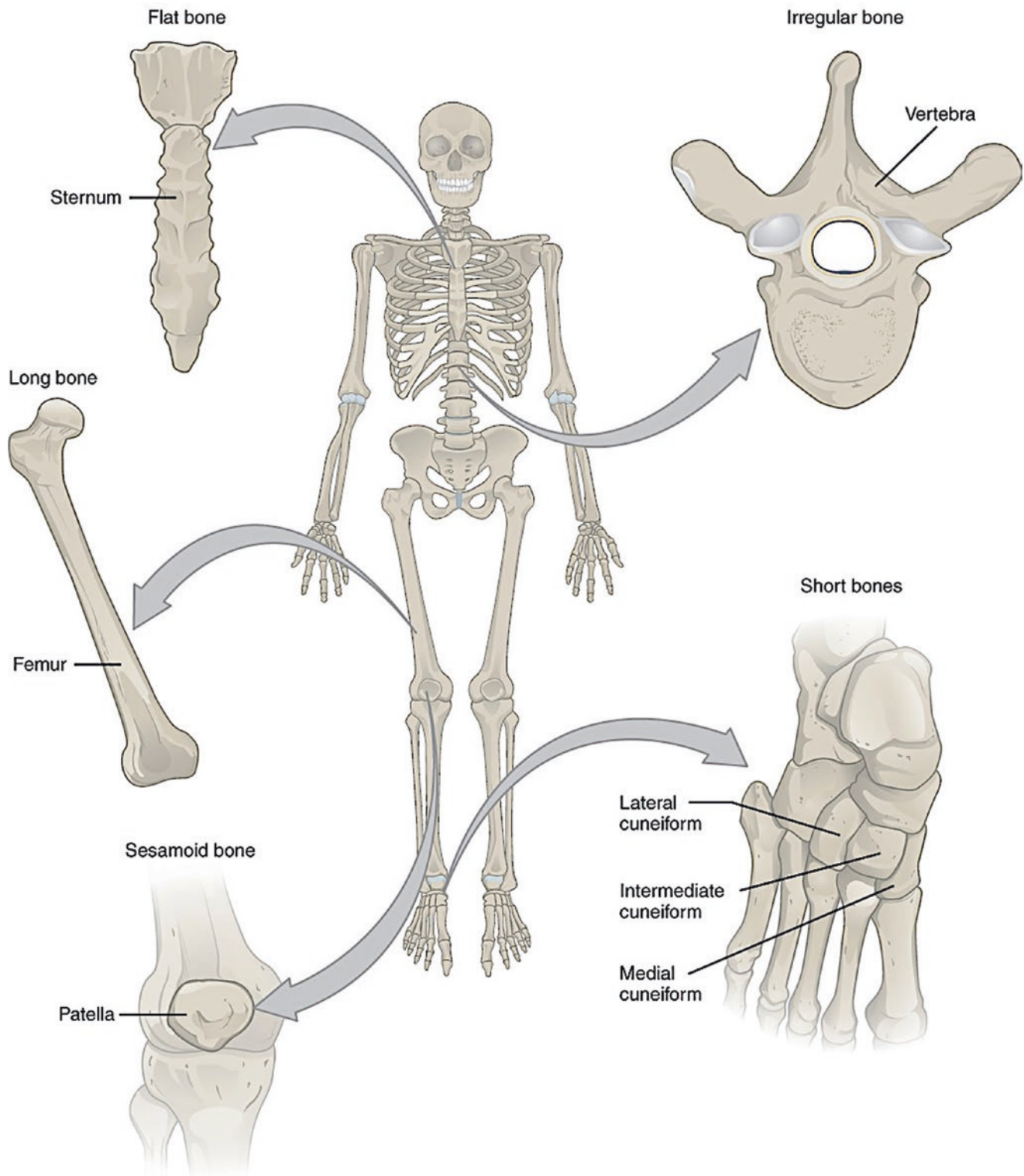
#### 2.4.1.1 Identification of the Fractured Bone

The identification of a fractured bone should be done according to generally accepted and standard anatomical terms.

#### 2.4.1.2 Bone Type

Generally bone consists of trabecular bone and cortical bone and it contains the bone marrow. It offers support, regulates the calcium metabolism and production of blood cells.

There are five types of bones in the skeleton with different characteristics and different functions: long, short, flat, sesamoid, and irregular bones (Fig. 2.1) [24, 25].



**Fig. 2.1** Types of bones (OpenStax College, 2013; licensed under the Creative Commons Attribution 3.0 Unported license, [https://commons.wikimedia.org/wiki/File:601\\_Bone\\_Classification.jpg](https://commons.wikimedia.org/wiki/File:601_Bone_Classification.jpg))

### Long Bones

Long bones are located in the appendicular skeleton (upper and lower limbs), have a cylindrical shape and are longer than they are wide. Long bones have several specific

functions of which the most important are supporting the body weight and facilitating movement (articulation).

They consist of diaphyses, epiphyses, metaphyses, and physes (growth plates). Long bones typically have a wide



metaphysis with thin cortex and an abundance of trabecular medullary bone whereas the diaphysis has a thick cortex and relative lack of trabecular bone (medullary cavity). The physis (growth plate) is situated between the epiphysis and metaphysis. At birth, virtually all epiphyses are cartilaginous and therefore not visible on radiographs. Ossification slowly progresses and is complete at adolescence. Some long bones, like the clavicle do not have a medullary cavity.

Typical long bones, like the humerus, radius, ulna, femur, tibia, and fibula, have two epiphyses (one at both ends), whereas some of the smaller long bones only have one epiphysis. Examples of smaller long bones are the phalanges, metacarpals, and metatarsals.

### Short Bones

Short bones are located in the wrist and ankles. Short bones are more or less equal in length, width, and thickness and can have any shape. Most of these bones are named according to their shape, e.g. the carpals in the wrist (scaphoid, lunate, triquetral, hamate, pisiform, capitate, trapezoid, and trapezium) and the tarsals in the ankles (calcaneus, talus, navicular, cuboid, lateral cuneiform, intermediate cuneiform, and medial cuneiform).

The function of short bones is to provide support and stability in parts of the skeleton, that are intended for strength and compactness with limited movement.

Short bones behave like epiphyses, both in normal growth and in pathology: they are almost all cartilaginous at birth and have a slow progressive ossification, they have a poor vascularization and therefore are prone to malunion or osteonecrosis after a fracture.

### Flat Bones

Flat bones are located in the skull (e.g. frontal, parietal, and occipital bone), the thoracic cage (sternum, ribs and scapula), and the pelvis (ilium, ischium, and pubis) and have a thin and curved shape with two prominent surfaces.

Flat bones form the boundaries of certain body cavities and their function is to provide protection for internal organs, like the brain, heart, lungs, and pelvic organs. Flat bones also provide large areas of attachment for muscles and are a major source of red bone marrow.

### Sesamoid Bones

Sesamoid ('sesame seed shaped') bones are small and round or irregular bones, which are embedded in tendons and joint capsules. Sesamoid bones vary from person to person in number and placement. The most common locations are the tendons of the hands, knees, and feet. Examples of this type are the patella and the pisiform bone.

The function of sesamoid bones is to provide protection of the tendons and the joint capsules by absorbing and redistributing weight-bearing forces and in that way decreasing stress on and wear of the tendons [26].

### Irregular Bones

Irregular bones are located in the axial skeleton (skull, spine, and pelvis). They vary in shape and structure and therefore do not fit into one of the other categories. They often have a complex shape. Examples of this type are parts of the skull, bones in the base of skull and some of the facial bones (e.g. temporal bone, zygoma, inferior nasal concha, mandibula), the vertebrae and parts of the pelvis (sacrum, coccyx, hip bone).

The function of irregular bones is to provide protection of internal organs, e.g. the vertebrae protect the spinal cord and the bones in the base of the skull protect (together with the flat bones of the skull) the brain.

A specific type of irregular bones are the so-called pneumatic bones, which are characterized by the presence of large air spaces, e.g. the maxilla, the mastoid, and the ethmoid. The function of these bones is not exactly known. These bones are relatively light and therefore considerably reduce the weight of the skull. These bones probably also play a role in the resonance of sound and in the temperature regulation of inspired air. Moreover, most of them are extremely thin-walled and therefore prone to fracture during trauma.

Because of the complex shape of irregular bones, it is often difficult to detect fractures with conventional radiographs and CT is preferred in cases with clinical suspicion but normal radiographs.

#### 2.4.1.3 Affected Part of the Bone

The description of the affected part of the bone depends on the type of bone.

In case of a long bone fracture, e.g. a fracture of the femur, the anatomic location of the fracture can be specified as diaphyseal (proximal, middle, or distal part), metaphyseal (proximal, distal), physeal, or epiphyseal (intra-articular, extra-articular). The fracture can further be specified by describing more specific anatomic terminology of the location, like condyle, malleolus, plateau, fossa, and tuberosity [19].

In case of flat bone fractures, e.g. rib fractures, the anatomic location should be specified by giving the number, ranking and laterality of broken ribs, as well as the location of the fracture(s) in the broken ribs: at the costochondral junction, in the anterior, lateral and posterior costal arch, or near the head or neck of the rib. For research purposes more elaborate descriptions have been proposed, which could also be used in detailed legal reports [27].

In case of an irregular bone fracture, e.g. a vertebral fracture, the anatomic location can be specified as fractures of cervical, thoracic, or lumbar vertebrae and of the corpus, arch, or transverse/spinous process. In a clinical situation classification schemes such as the ThoracoLumbar Injury Classification and Severity Scale (TLICS) could be used [28].

The reader is referred for an extensive description of affected parts of the different bones to Chaps. 5–12.

**Table 2.4** Type of fracture and direction of fracture lines in long bones

Complete fracture	Fracturing of a bone, causing separation into two or more pieces
Simple	• Only one single fracture line (a.k.a. single)
• Longitudinal	• The fracture line runs parallel to the long axis of the bone (a.k.a. longitudinal)
• Transverse	• The fracture line runs more or less perpendicular at an angle of less than 30 degrees in relation to the long axis of the bone
• Oblique	• The fracture line runs more or less oblique (diagonal) at an angle of over 30 degrees in relation to the long axis of the bone
• Spiral	• The fracture line ‘circles’ around the long axis (cork-screw), and the fracture line runs oblique in relation to the central axis
	With conventional radiology, it is not always possible to distinguish between an oblique and a spiral fracture.
Multifragmentory	• Multiple (three or more) fragments (a.k.a. comminuted or complex)
• Wedge–butterfly	• Triangular (shape of a butterfly wing) fragment between two larger bone fragments
• Segmental	• Fracture in two places with a ‘floating and unattached’ segment between two well-defined fracture lines
Incomplete–partial fracture	• The fragments are still partially joined and the fracture does not completely traverse the width of the bone
• Bowing	• The bone deformed past the point at which, based on the elasticity of the bone, spontaneous recovery is the rule • No radiologically visible cortical damage
• Greenstick	• The cortex at the tension side is damaged with an intact cortex and intact periosteum at the compression side
• Torus–buckle	• The cortex at the compression side is damaged with an intact cortex and intact periosteum at the tension side

### 2.4.2 Type of Fracture and Direction of Fracture Lines

The type of fracture, the direction of fracture lines, and the terms used to describe type and direction are determined mainly by the type of fractured bone. An overview of terms in long bones is given as an example in Table 2.4. The reader is referred to Chaps. 5–12 for more detailed information.

### 2.4.3 Position and Relationship of the Fracture Components

The position and relationship of the fracture components and the terms used to describe position and relationship again are determined mainly by the type of fractured bone. An overview of terms in long bones is given as an example in Table 2.5. The reader is referred to Chaps. 5–12 for more detailed information.

**Table 2.5** Position and relationship of the fracture components

Fracture displacement	abnormal position of the distal fracture fragment in relation to the proximal bone
Non-displaced	• The fragments of the fracture are aligned
Displaced	• The fragments of the fracture are not aligned and there is a gap between the two ends of the bone
• Translated or ad latus	• The bone fragments are sideways displaced
• Angulated	• The fragments are displaced with an alteration of the normal axis of the bone, causing the distal portion to point in another direction than the proximal part: • Dorsal/palmar • Varus/valgus
• Rotated	• The distal component is rotated compared to the proximal component.
• Shortened	• The total bone length is reduced: • Impaction = telescoping of two fragments into each other, • Compression = crushing of two fragments, causing the broken bone to be wider or flatter in appearance, • Compression and wedging = (usually occurring in the vertebrae) the front portion of a vertebra in the spine has collapsed • Overriding = overlap of two completely displaced fragments (a.k.a. ‘dinner fork’ or ‘bayonet’ fracture)
• Avulsion	• A fragment of the bone is pulled off, often by a tendon or ligament

**Table 2.6** Complications

Concerning the stability of the fracture	
Stable	• Fragments line up and are barely out of place.
Unstable	• Fragments tend to shift further out of place.
Concerning the integrity of overlying skin and soft tissues	
Closed	• The bone is broken, but the overlying skin has not been ruptured and remains intact (a.k.a. simple), without or with soft tissue injury.
Open	• The bone is broken and the overlying skin and soft tissues are either pierced by the broken bone or by the blow that has broken the skin at the time of the fracturing of the bone. The bone may or may not be protruded through the skin (a.k.a. compound or complex). An open fracture carries a high risk of infection.
Concerning joint involvement	
No	
Yes	• Articular • Joint dislocation

### 2.4.4 Complications

In Table 2.6, an overview is given of possible complications of fractures concerning the stability of the fracture, the integrity of overlying skin and soft tissues and joint involvement.

## 2.5 Cause of Fractures (Mechanism)

### 2.5.1 General Aspects

In a forensic setting, a (physical) trauma is defined as an event which can result in an injury (physical harm, bodily injury, physical injury) (see Sect. 1.4). An injury is defined as any wounding or physical damage that results from the (sudden) subjection of the body or parts of the body to amounts of energy that exceed the threshold of mechanical tolerance, in other words, that are beyond the body's ability to absorb the transferred energy, with or without externally visible damage to the skin or the mucous membranes and/or with or without signs of damage to the skeleton or internal organs [29, 30]. In brief an (hard or soft tissue) injury is caused by loading of that tissue beyond its failure threshold (the maximum load-bearing capacity). In case of fractures (hard tissue injury): fracturing of bone or cartilage will occur when the loading of a bone or the cartilage exceeds the failure threshold.

Fracturing can occur in normal bone, but also in abnormal/weakened bone. In normal bone the loading will have to be substantial with a high transfer of energy. If a bone is fractured and there is no evidence of a trauma with a high transfer of energy, this may indicate the presence of generalized or more localized abnormal/weakened bone.

Although high and a low-energy trauma are well-accepted terms in the medical literature one should realize these terms are not well defined by exact numbers and measures, but by using general descriptions and comparing types of trauma, supported by examples of types of accidents. Like high and low pressure in static loading (Sect. 1.5.2.1). These terms should be considered subjective and relative with a grey area between low- and high-energy transfer and depending on the context in which these terms are used.

Often used synonyms are trauma (collisions) with high or low transfer of energy and high or low velocity trauma (collisions).

What type of injury is sustained, depends not only on the amount of transferred energy, but also on the specific characteristics of the trauma:

- Type of mechanical trauma:
  - Blunt force trauma: non-penetrating/penetrating.
  - Sharp force trauma: penetrating/non-penetrating.
  - Compression/crushing, tension, shearing and bowing, and combinations of these mechanisms, e.g. compression and bowing (see Chap. 12, concerning long bone fractures).
- Type of collision:
  - Moving object impacting static body or moving body impacting static object.

- Body and object both moving: same direction (front to back collision), opposite direction (front to front collision), and/or angled (side to side collision).
- The amount of transferred (=absorbed and returned) energy.
- The nature of the object and the impact site on the body, including the structures underneath the skin.

### 2.5.2 High-Energy Trauma

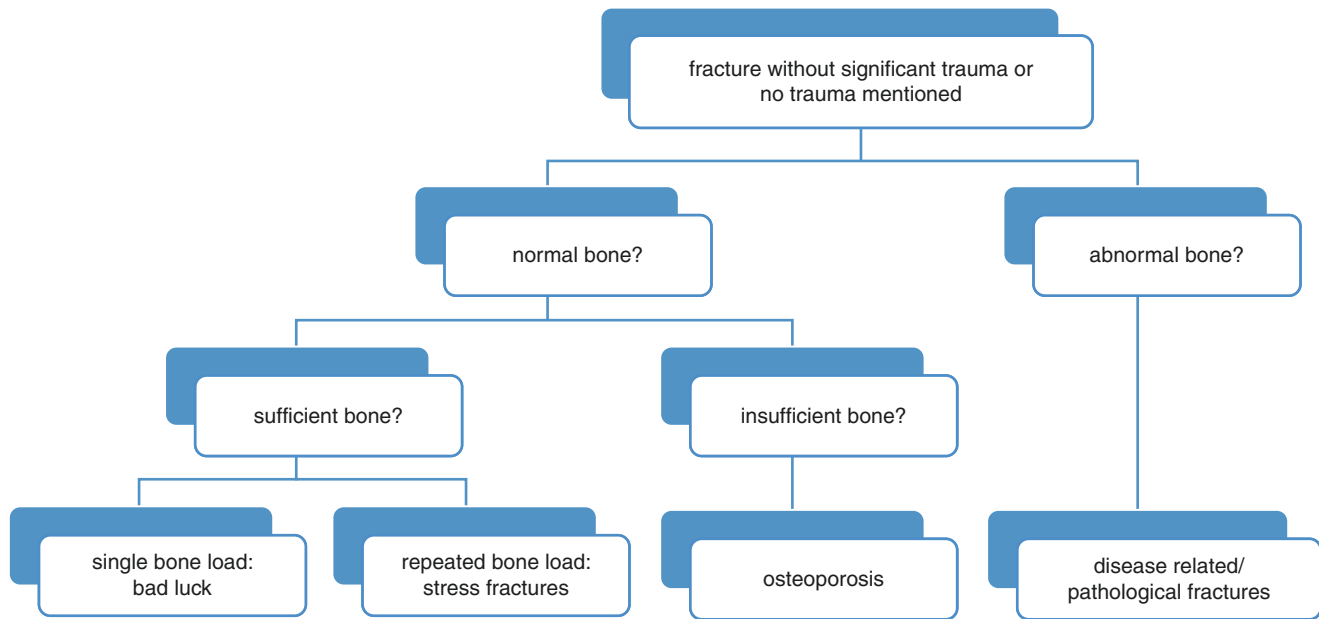
A high-energy trauma is commonly described in the literature as a trauma in which the body of a person is exposed to the transfer of high amounts of energy. The transfer of energy can be mechanical or thermal (heat or cold, but also temperature generated by chemical agents or electricity) in origin.

Mechanically transferred energy can be converted into kinetic energy. Kinetic energy is the energy contained in a moving object or body. The amount of the transferred kinetic energy (KE) can be calculated and is determined by the mass and velocity of the moving body/object:  $KE = \frac{1}{2} \times \text{mass} \times \text{velocity}^2$  (mass in kilograms, speed in metres per second, kinetic energy in joules). This formula shows that velocity is a more important determinant of the amount of transferred kinetic energy than mass. If the mass doubles, the transferred kinetic energy doubles but if the velocity doubles, kinetic energy quadruples.

A high-energy trauma usually will result in more serious injuries, like fractures, intracranial injuries, neck injuries, and/or injuries to internal organs, compared to a low-energy trauma.

Although exact numbers and measures concerning high- and low-energy trauma (collisions) are lacking guidelines for adults make use of examples like:

- Long-distance falls (at least 2–3 times body length).
- Motor vehicle accidents:
  - Motor vehicle versus pedestrian—speed of vehicle above 10 km/h.
  - Motor vehicle versus pedestrian—pedestrian run over or thrown.
  - Motor vehicle collision without seat belt—speed above 35 km/h.
  - Motor vehicle collision with seat belt—speed above 45 km/h.
  - Motor vehicle versus moped or motor collision with a speed difference above 35 km/h.
  - Accident in which the vehicle has been moved more than 7 metres.
  - Accident in which the engine or a wheel of the car has penetrated into the passenger compartment.
  - Distortion of the steering wheel.



**Fig. 2.2** Flow chart for the evaluation of a fracture when no (significant) trauma is reported

- Release of airbags.
- Accident with a car with an indentation of the passenger compartment above 35 cm on the victim’s side and/or above 50 cm on the other side.
- Collision in which the front axle of a car has been moved backwards.
- A star break in the windscreen caused by the unrestrained passenger.
- Hair and/or blood on the interior mirror.
- Knocking over of the vehicle.
- Ejection from a vehicle.
- Helmet damage or no helmet worn.
- Seriously injured or deceased victim in the vehicle.
- Vehicle deformation.

The reader is referred to Chaps. 5–12 for an extensive description of fractures in children due to high-energy trauma.

### 2.5.3 Low-Energy Trauma

In the medical literature, a low-energy trauma is described in many different ways. This is usually done by using examples, just like in high-energy trauma, e.g. a slip, a trip, or a fall from standing height or less. Sometimes it is described as a trauma due to the transfer of an amount of energy of which it is assumed that such an amount would not result in a fracture. Finally it may be described merely by excluding the presence of a high-energy trauma [31].

If a bone is fractured and there is no evidence of a high-energy trauma or there is only a minor trauma or even no trauma mentioned in the medical history, one should start by answering the questions, which are visualized in Fig. 2.2.

#### 2.5.3.1 Low-Energy Trauma: Normal Sufficient Bone—Single Load

Despite the fact that most fractures are caused by the transfer of high amounts of energy, caused by large mass or high velocity, one should realize that fractures can also be caused by a trauma that at first sight seems to be a low-energy trauma (Sect. 2.5.1). In such a seemingly low-energy trauma, it is often the case that the location where a small force acts creates a high torque around a rotation point, relatively far away from that location. This results in a large force at a fracture site close to the rotation point, due to the difference in moment arms, amplifying the small input force. Strictly speaking a small force acting over a large distance (force  $\times$  distance = work) still creates a large transfer of energy. Nonetheless in a clinical setting this is considered to be a low-energy trauma. These fractures are sometimes characterized as ‘bad luck’.

Probably the most common fracture in this category is the so-called toddler’s fracture (Childhood Accidental Spiral Tibia (CAST) fracture), although Jaimes et al. are of the opinion that this fracture is the most common stress fracture (in biomechanics known as fatigue fracture) in young children [32]. The toddler’s fracture is a non-displaced oblique fracture of the tibia shaft or the distal portion of the tibia. This type of fracture typically occurs between the age of

9 month and 3 years at the onset of ambulation [32]. A child with this fracture will refuse to bear weight on the fractured leg. The fracture probably is the result of an often not recognized acute more or less minor trauma, e.g. a torsional force when a toddler stumbles and falls on a positioned foot. According to Jaimes et al., toddler's fractures may also (less common) occur in other weight-bearing parts of the skeleton, like the fibula, the posterior part of the calcaneus, the base of the cuboid, and the talus [32].

In older children, a low-energy trauma in normal sufficient bone due to a single load may also result in a fracture: spraining an ankle during football is considered to be a low-energy trauma. The same movement, that results in spraining, may also result in a fracture of the tibia or fibula.

Some fractures, e.g. of the radius, ulna, and clavicle may also be the result of low-energy trauma in short distance falls due to falling on an outstretched hand (FOOSH) (see also Sects. 2.1.2, 8.2.2 and 12.5.3.3).

### 2.5.3.2 Low-Energy Trauma: Normal Sufficient Bone—Repeated Load

Repeated loading of normal sufficient bone may lead to an accumulated trauma to normal bone, resulting in overuse fractures due to a mismatch between on the one hand the burden of activity on bone and cartilage (the loading of the bone and cartilage) and on the other hand the load-bearing capacity of bone and cartilage (the intrinsic biomechanical properties and the intrinsic ability of the bone and cartilage to repair itself—the ability of bone and cartilage to absorb energy) [32, 33]. This type of fractures, due to overuse, caused by accumulated trauma, can be divided into avulsion fractures and fatigue fractures.

#### Avulsion Fractures

Avulsion fractures are more common in skeletally immature children and in adolescents. Examples of avulsion fractures in paediatric and adolescent patients are the classical metaphyseal lesion (Sect. 12.3.2) and the apophyseal avulsion fractures of the pelvis (Chap. 11).

#### Fatigue Fractures in Normal Bone: Stress Fractures

In the medical literature, fatigue fractures in normal bone and stress fractures are used as synonyms, describing (usually non-displaced hairline) fractures that occur in a bone after the bone has been subjected to repeated stresses (overuse—accumulated trauma), rather than one single sudden impact trauma. Stress-related fracturing occurs when muscles have become fatigued and are no longer able to absorb added/repeated shock. The overload of stress is then transferred to the bone, resulting in a stress fracture. None of these stresses would individually be large enough to cause a fracture, in a person without an underlying disorder with increased bone fragility, but the intrinsic ability of the bone

to repair itself is exceeded by the repetitive character and frequency of the loading [33–35].

Stress fractures in adolescents and adults are most commonly sustained during sports, heavy physical exercise/labour. Most stress fractures occur in the weight-bearing bones of the lower leg and the foot (e.g. in runners: metatarsal bones). More than 50 percent of all stress fractures in adolescents and adults occur in the lower extremity [34].

Stress fractures also occur in paediatric patients. According to Griffiths, stress fractures had been described in children as young as 15 months [36]. He cited a 1942 article by Siemens, who 'described a case of bilateral fatigue fracture of the middle third of each fibula in a boy of 15 months', and in his article himself described stress fractures in paediatric patients in the tibia (mostly in the proximal third), in the fibula and furthermore in the humerus, first rib, pelvis, medial sesamoid bone of the hallux, metatarsal bones (so-called march fractures), and femur.

The incidence of stress fractures in the paediatric population seems to be increasing, supposedly because more children are participating in organized and recreational sports at a younger age [32, 37–39]. Contributing factors to the increasing occurrence in paediatric patients is probably the combination of an underdeveloped musculoskeletal system/skeletal maturation, increased participation in competitive sport at a younger age, and increased duration and intensity of training, e.g. year-round activities [32, 38, 39]. Shelat and El-Khoury and Wu et al. also were of the opinion that many of the overuse injuries, including stress fractures, may go underreported and/or underdiagnosed, because they may also occur in other circumstances, than sporting, or are not recognized in imaging, because stress fractures can be radiographically occult [38, 39].

In older children and adolescents, mainly in athletes, fatigue fractures are found in the femur (inferior surface of the neck, shaft, and distal metaphysis), tibia, spine (spondylolysis), acromion, metatarsal and tarsal bones, pelvic bones, and upper extremity (e.g. little leaguer's shoulder or elbow, gymnast's wrist) [32, 38, 39].

Devas and Jaimes et al. mentioned that one should be aware that a stress fracture in a child might resemble an infection, e.g. osteomyelitis, or malignant bone tumour [32, 40]. Also benign bone tumours, like osteoid osteomas, may suggest stress fractures for an unexperienced radiologist. Therefore cross-sectional imaging and expert evaluation in these cases are mandatory.

### 2.5.3.3 Low-Energy Trauma: Normal Insufficient Bone

It is often stated that fractures in children usually are caused by trauma but that certain bone disorders, that 'weaken' the bone, also may cause fractures. This would concern bone disorders with normal but insufficient bone (= normal but not

enough bone), but also medical conditions with increased risk of fracturing due to weakened bone (see Sect. 2.5.3.4).

The statement that bone disorders may cause fractures is not correct. Bone disorders do not cause fractures, but may increase the risk of fracturing with a lower load.

A single load or repeated loading of normal but insufficient bone, e.g. in osteopenia and osteoporosis, can lead to overuse fractures due to a mismatch between the loading and the ability of the normal but insufficient bone to withstand the load.

In the medical literature, fractures in normal but insufficient bone are often referred to as spontaneous fractures: ‘*fractures that occur without a clear demonstrable external (= traumatic) cause*’ [41]. Torwalt et al. described a 4-year-old boy with cerebral palsy and palsy after a non-accidental head trauma [41]. The post-mortem radiographs of the boy showed fractures at various stages of healing in the left humerus and both femurs, tibiae and fibulae. Based on a comprehensive investigation, child abuse, accidents, metabolic diseases, other primary and secondary bone diseases and pathological fractures could be excluded. They concluded that the multiple fractures in this boy were ‘spontaneous’ fractures secondary to osteopenia, although in our opinion another conclusion could also have been drawn. Based on the information given by the authors, one could also state that no cause was found and that inflicted injuries could not be excluded beyond reasonable doubt.

#### 2.5.3.4 Low-Energy Trauma: Abnormal Bone

As stated in the foregoing section, medical conditions can lead to an increased risk of fracturing due to weakened bone. Just as in normal but insufficient bone fracturing may be caused by a single load or by repeated loading of the weakened bone.

In the medical literature, a fracture due to a medical condition with weakening of the bone is often referred to as a ‘pathological’ fracture: a fracture in bone tissue, that is pathological, weakened and remodelled by an underlying disorder, with altered or reduced mechanical and viscoelastic properties [42].

The list of medical conditions with an increased risk of fracturing due to weakened bone is very extensive. An overview of medical conditions (not all inclusive) with increased risk of fracturing is given in Table 2.7. Medical conditions that cause reduced bone strength can be congenital or acquired. These disorders are either generalized (diffuse, systemic) throughout the skeleton (e.g. osteogenesis imperfecta) or more localized (focal) (e.g. osteomyelitis or demineralization of one limb, resulting from prolonged immobilization). Disorders are either due to more or less benign disorders or to malignant disorders. Most ‘pathological’ fractures are due to benign tumours, but can also be due

to tumour-like lesions, metabolic diseases (e.g. osteogenesis imperfecta, osteopetrosis), bone infections (e.g. osteomyelitis), and neuromuscular disorders. Pathological fractures due to malignant disorders (e.g. sarcomas, leukaemia, bone metastases) are much rarer [42–44]. According to Boyce and Gafni, many of these conditions are easily diagnosed or excluded with a thorough history, physical exam, and selected diagnostic tests [43].

The most important and probably most common medical condition with an increased risk of fracturing due to weakening of bone is osteogenesis imperfecta (OI). In 2013, Greeley et al. published the results of a retrospective study into the presence of fractures in 68 children with osteogenesis imperfecta [49]. They found that most fractures in children with OI occurred in the extremities: arms (17×) and legs (36×). Rib fractures were found in 15 children. In 13 out of 15 children with fractured ribs, they were diagnosed prenatally (before birth) or immediately after birth as the result of OI. The rib fractures of the 2 remaining children were diagnosed at the age of 14 and 43 months. This involved children with OI type 1 (plus a positive family history and blue ‘eye white’). The number of fractures present at the time of diagnosis varied from 1 to more than 37, with 7 children (10%) having more than 2 fractures. All children with more than 2 fractures were diagnosed before or immediately after birth. Seventeen children (25%) were diagnosed after the first week of life, but before the age of 12 months. None of these children had more than 1 fracture at the time of diagnosis. Almost 75% of the children were diagnosed on the basis of the findings from the clinical examination. According to Greeley et al., finding multiple rib fractures is an unlikely finding in children under the age of 1 year with OI [49].

#### 2.5.3.5 The Use of Terms like Spontaneous and Pathological Fractures in Forensic Paediatrics

From a clinical point of view, the use of terms like ‘spontaneous’ and ‘pathological’ in relation to the occurrence of fractures is understandable and even acceptable. However, from a biomechanical point of view the use of these terms as an explanation for the occurrence of a fracture or multiple fractures in a child with a bone disorder is an approach that is too limited, and as such incorrect. Fracturing of a bone is determined by the load exerted on the bone as well as the load-bearing capacity of the bone. ‘Spontaneous’ and ‘pathological’ only pertain to the capacity of the bone to absorb stress. Based on the use of these terms, one only and implicitly concludes that it would be possible for weakened bone to sustain a fracture not only with a minimal trauma or during normal care but even without a trauma.

A bone disease may decrease the maximum loading capacity/resistance of the bone against fracturing, resulting

in a lower resistance against loading and therefore in an increased risk of fracturing. A fracture in weakened bone is, just like in normal bone, caused by the exceeding of loading over the maximum load-bearing capacity of a bone (the capacity to absorb stress), in other words, it is caused by a trauma. As a result of the loading, the weakened bone breaks.

From a forensic point of view, the use of ‘spontaneous’ or ‘pathological’ may also lead to false certainties, related to the manner, when one has to differentiate between accidental and non-accidental circumstances based on these terms. By using these terms the manner of the fracture is not taken into consideration at all. When a fracture is found in a child, the presence of a disorder that results in a decreased capacity to absorb stress says nothing about the circumstances in which the stress was exerted. The medical history and the clinical/radiological symptoms may indicate whether the fracture was sustained in accidental and non-accidental circumstances.

Fractures in normal but insufficient bone and in weakened bone occur when the strength of a bone is reduced to a level that stresses that normally would not fracture a healthy bone will break the weakened bone (reduced maximum load-bearing capacity) [35, 50]. If fractures are found in a young and non-mobile child without any plausible explanation, a fracture in normal but insufficient bone or in weakened bone should be considered (Table 2.7). The determination of the possible presence of an underlying condition and the circumstances under which the fracture occurred are based on the medical history of the child (and the family), clinical examination (including laboratory examination), and radiological assessment [42].

**Table 2.7** Medical conditions with an increased risk of fracturing (not all inclusive) [42–48]

<i>Benign congenital disorders</i>	
	Osteogenesis imperfecta and variants like Bruck syndrome
	Copper deficiency in infants
	Ehlers–Danlos syndrome
	Menkes syndrome
	Metabolic bone disease of prematurity
	Neuromuscular diseases, e.g. Duchenne muscular dystrophy
	Vitamin D-resistant rickets (or hypophosphataemic rickets)
	X-linked hypophosphatemia
	Liver defects, e.g. Alagille syndrome
	Malabsorption
	Familial osteoporosis
	Osteopetrosis
	Cole carpenter syndrome
	Congenital CMV infection
	Insensitivity to pain, e.g. in spina bifida and in congenital pain insensitivity
	Neurofibromatosis type 1
	Osteopetrosis
	Pycnodysostosis
	Idiopathic juvenile osteoporosis

**Table 2.7** (continued)

<i>Benign acquired disorders</i>	
	Infections, e.g. osteomyelitis
	Vitamin D deficiency based on nutritional defects: Rickets
	Intoxications, e.g. with lead
	Prolonged reduced mobility, e.g. in cerebral palsy or posttraumatic
	Paediatric inflammatory bowel disease, e.g. Crohn’s disease (due to, among others, direct effects of inflammation, prolonged use of glucocorticoids, and poor nutrition)
	Benign bone tumours, e.g. non-ossifying fibroma, osteochondroma, chondroblastoma, enchondroma, giant cell tumour, and osteoid osteoma
	Renal osteodystrophy, due to chronic renal diseases and concurrent vitamin D deficiency/rickets and secondary hyperparathyroidism
	Diabetes mellitus
	Mastocytosis
	Bone cysts, e.g. unicameral bone cyst and aneurysmal bone cyst
<i>Iatrogenic conditions</i>	
	Radiation therapy
Use of	Diuretics
	Glucocorticoids
	Anticonvulsants
	Antiretrovirals
	Methotrexate
	Bisphosphonates
	Prostaglandins
<i>Malignant disorders</i>	
	Leukaemia
	Isolated metastases/metastatic tumours (e.g. Wilms tumour, neuroblastoma)
	Ewing sarcoma
	Osteosarcoma
	(congenital) fibrosarcoma
	Eosinophilic granuloma
	Langerhans histiocytosis

## 2.6 Manner of Fractures (Circumstances)

As stated in the foregoing sections, a fracture is always caused by a trauma, whether the bone is normal, weakened, or overused. The circumstances under which a trauma occurs (manner) can be accidental or non-accidental. Trauma can occur intrauterine, during birth or after birth.

### 2.6.1 Intrauterine Fractures

As far as known from the medical literature intrauterine acquired fractures (fracturing of a foetal bone in utero) are only rarely reported [51–54]. The first descriptions are found in the medical literature in the early and mid-nineteenth century [55–57]. Some of the first descriptions, in the early 1900s, in radiology were by Smith and Snure [58, 59].

In utero fractures occur due to trauma in normal or in weakened bone, just like fractures that are sustained during and after birth. According to Morgan and Marcus, ultrasound is the best imaging modality for identifying foetal fractures of any aetiology, while biochemical and genetic tests can aid in the prenatal diagnosis of congenital disorders like osteogenesis imperfecta [53]. According to Dawson, the presence of signs of healing on imaging of normal bone within the first days after birth would rule out an obstetrical fracture [60].

### 2.6.1.1 Intrauterine Fractures in Normal Bone

Skull fractures, although rarely reported, are the most commonly described intrauterine fractures in medical literature [52–54]. These fractures can be true fractures with clearly recognizable fracture lines, but mostly reported are depressed skull fractures, so-called ‘ping-pong’ fractures, which are characterized by inward buckling of the calvarian bones (Sects. 5.3.3.1, 5.3.3.2 and 5.3.4.5) [61].

Isolated intrauterine femur fractures have also been described. Several authors described the fracture of the femur, after ruling out other possibilities, as occurring spontaneous/without any known trauma, others as being caused by maternal blunt force trauma of the pelvis, e.g. due to falls, motor vehicle accidents, or domestic violence [62–67].

Finally fractures of the tibia and fibula, spine and clavicle have been described (mostly as single case reports) as intrauterine acquired fractures, which were not disease related [60, 68–73].

### 2.6.1.2 Intrauterine Fractures in Weakened Bone

Intrauterine fractures in weakened bone have been described due to several medical conditions. Osteogenesis imperfecta is the most prevalent disorder, but other genetic/metabolic disorders can be found [53]. Dawson also mentioned chondrodystrophies and congenital syphilis [60]. Some of these disorders result in severe handicaps after birth or are not compatible with life intrauterine or after birth [74–78].

## 2.6.2 Fractures During Birth: Birth Trauma

### 2.6.2.1 General Aspects of Birth Trauma-Related Fractures

In older children, pain is often a more or less reliable indicator for the presence of a fracture. However, in neonates it is difficult to establish pain and therefore a fracture can only be diagnosed by carefully observing behaviour, muscle tone, heartbeat and symptoms such as nausea and vomiting or limited use of a body part [79].

Fractures resulting from birth are not always diagnosed immediately post-partum, unless there are obvious symptoms, such as a clearly visible swelling and/or abnormal

position. It is quite likely that physicians will overlook some fractures due to the lack of obvious symptoms. Research by Morris et al. showed that there was a delay in diagnosis in the majority of children that had sustained a birth trauma-related femur fracture (Sects. 12.7.2.3, 12.7.3.3 and 12.7.4.3) [80]. Skull fractures are found in 5% of the children born by vacuum extraction, but are frequently overlooked unless a routine radiograph is made [81]. Clavicle fractures too are often diagnosed as late as several weeks after birth, due to the then present callus formation [82].

This delay in diagnosis can lead to wrongfully suspected non-accidental circumstances (child abuse). To a certain extent it is possible to differentiate between birth trauma-related fractures and fractures that are sustained after birth by carefully evaluating the presence of callus formation:

- Kogutt et al. stated that under normal circumstances, a fracture that is diagnosed 10 to 15 days after birth cannot be considered resulting birth, if there is no evidence of healing (subperiosteal new bone formation or callus formation) [83].
- Cumming reported that callus in the healing of birth-related fractures may be visible as early as 7 days after birth [84].
- Walters et al. evaluated 131 radiographs of presumed birth trauma-related clavicular fractures and rarely did find subperiosteal new bone formation before day 7 after birth, but it was most often present at day 10 [85]. Callus formation was rarely seen before day 9, but it was most often present at day 15.
- Fadell et al. reviewed retrospectively a total of 108 digital images of 61 infants with clavicular fractures [86]. Their findings are summarized in Table 2.8.

### 2.6.2.2 Incidence and Prevalence of Fractures Resulting from Birth

Jaarsma considered the incidence of birth trauma-related fractures to be 0.1–3.5% [79]. In the medical literature, a great number of studies can be found on fractures resulting from delivery (Table 2.9) [87–89]. Based on these publications it has been established that clavicular fractures are the most common birth-related fractures, followed by fractures of the humerus, skull, and femur. Rib fractures are only reported in exceptional situations (see Sect. 7.3.2) [91].

**Table 2.8** Indicative timescale of healing in birth trauma-related clavicular fractures [86]

Feature of healing	First seen at day	Peak period (days)
Periosteal reaction	7	11–42
Callus	11	12–61
Bridging	20	22–63
Remodelling	35	49–59



**Table 2.9** Fractures resulting from delivery (not all inclusive)

Author(s)	neonates (N)	Number of fractures (%)	Location	N	%
Rubin [87]	15,435	51 (0.35)	Clavicle	43	84.3
			Humerus	7	13.7
			Skull	1	1.6
Camus et al. [88]	20,409	123 (0.6)	Clavicle	105	85.4
			Humerus	7	5.7
			Skull	7	5.7
			Femoral shaft	2	1.6
			Epiphysis	2	1.6
Bhat et al. [89]	34,946	35 (0.1%)	Clavicle	16	45.7
			Humerus	7	20.0
			Femur	5	14.3
			Skull	4	11.3
			Orbit	1	2.9
			Epiphysis	1	2.9
			distal femur	1	2.9
			Dislocation elbow		
Groenendaal and Hukkelhoven [90]	158,035	1174 (0.7)	Clavicle	Number of fractures not reported	
			Humerus		
			Femur		
			No other fractures mentioned		

Bhat et al. found a higher incidence of fractures in cases without prenatal care, after a complicated delivery or after a Caesarean section [89].

In 2007, Groenendaal and Hukkelhoven drew attention in the Netherlands Journal of Medicine to the prevalence of fractures in term neonates [90]. They used data from Perinatal Registration Netherlands which contains data on term neonates <28 days old ( $n = 158.035$ ). In 1174 children (0.74%) fractures were found. In 19% ( $n = 227$ ) of cases, the cause of the fracture was not known: the vaginal birth had been either physiological and reported to be non-traumatic or there had been an uncomplicated Caesarean section; after the delivery there had been no cause for resuscitation and further diagnostics showed no indications for congenital bone diseases such as osteogenesis imperfecta or osteopenia. Twelve of the 227 children had sustained a humerus fracture without known cause, and 3 a femur fracture. The remaining 212 children had sustained a fracture of the clavicle. Groenendaal and Hukkelhoven suspected that the number of fractures in term neonates in The Netherlands would be higher than the 0.74% they found [90].

Many of the fracture-types that are found in non-accidental trauma have also been reported as occurring as birth trauma-related, usually in case reports. Hence, it is essential that in the immediate period after birth, a thorough obstetric history is taken. This history should also include the nurses notes, as often they will be the first to note that a child doesn't move a limb properly or shows pain during daily handling.

### 2.6.3 Fractures After Birth: Accidental Circumstances

While growing up, a child becomes more mobile and starts to discover the world around him. Due to this the risk of accidental injury increases [1].

Between the ages of 1 and 4 years and in older children (>10 years), a fracture is most commonly due to accidental circumstances [15]. In the group of children between the ages of 1 and 4 years, fractures of the upper extremities and the clavicle are most common, due to the reflex of the child to catch itself on the stretched arm when falling. In children over 10 years of age, the number of traffic accidents will be higher than in younger children [92] (Sect. 2.1.2).

### 2.6.4 Fractures After Birth: Non-Accidental Circumstances

#### 2.6.4.1 Epidemiology

In children under 1 year of age, one will find fractures due to accidental circumstances only in a small minority of cases [92]. After bruises and burns, fractures are the most prevalent inflicted injuries [93, 94]. Fractures have been described in 55% of children who were victims of physical violence [83, 95].

The finding of inflicted fractures in children indicates the use of severe violence, which emphasizes the importance of a correct diagnosis. Sinal and Stewart found that fractures were the first sign of non-accidental trauma in 17% of the children with inflicted injuries [96].

Approximately 10% of children under the age of 5 years who because of an injury are seen by a physician in emergency departments in the United States have inflicted injuries, including fractures [97]. In children evaluated in emergency departments because of a suspicion of inflicted injuries, over 30% appears to have fresh or healing fractures [98].

In a study, in air force personnel in the United States, on child homicide between the ages of 1–15 years (average 3.9 years) it was found that 55% of these children had been seen by a physician because of physical injuries, including fractures, in the month prior to their death [99].

Rang poses that as many as 25% of all fractures in children of less than 3 years of age are inflicted and/or due to neglect [15]. According to Akbarnia et al., inflicted fractures occur predominantly in children of less than 1 year of age [100]. Based on various studies, it is estimated that 50 to 70% of all fractures in children of less than 1 year old are inflicted and/or due to neglect [101, 102]. It was also shown that children in this age group are at a high risk of sustaining inflicted injuries, including fractures, again, even after an intervention took place [103].

Unfortunately in these young, often non-mobile, children fractures are often not recognized because of several reasons. Firstly fractures in this young children can have an occult course, because fractures in these children often show no or hardly any clinically conspicuous symptoms such as swelling, redness, tenderness or pseudo-paresis [13, 14, 104]. Secondly in these children (inflicted) fractures remain not only unnoticed due to its occult course, but also because non-accidental circumstances are not or inadequately considered, or even rejected on non-plausible grounds:

- Between 1995 and 1999, Banaszkiwicz et al. carried out a retrospective study in all children under the age of 1 year which were brought into the emergency department of their hospital because of fractures [105]. The data of 74 children in total were re-evaluated. The average age of the children was 5 months (2 weeks to 1 year). Forty-six children had sustained a skull fracture. In 28 children, there was a fracture of the long bones. After analysis, it appeared that the attending physician failed to assess possible non-accidental circumstances correctly in nearly 30% of these children. In nearly 50% of children, the medical data did not show that non-accidental circumstances had even been considered, whereas in retrospect non-accidental circumstances would have been a plausible explanation in the differential diagnosis.
- Oral et al. carried out a similar retrospective study in 653 children of 3 years and younger who presented with a fracture over the period 1995–1999 [106]. The aim of their study was to establish whether in this group of children physicians inquired sufficiently into the circumstances, under which the fractures occurred. Revision showed that, based on the data in the dossier, in 42% of children it had not been possible to exclude that the fractures were inflicted (non-accidental injury/child abuse). The missing data concerned:
  - Information on the presence of (independent) eye-witnesses at the moment the fracture was sustained.
  - Information on previous injuries.
  - Revision of previous medical data.
  - Description of associated injuries.
  - An evaluation to see whether the reason provided and the injury of the child could be explained when taking into account the level of development of the child.
- Consequently, Oral distinguished four groups: accidental injury (63%), non-accidental injury ('inflicted injury') (13%), missed non-accidental injury (23%), and missed accidental injury (0.6%) [106]. Factors that had a positive influence on identifying non-accidental circumstances were the age of the child, the presence of multiple fractures, and an examination by a paediatrician.

- Carty and Pierce reported on a cohort of 467 children who were either presented at the or referred to the Alder Hey Hospital, Liverpool UK, with a suspected diagnosis of child abuse during a 13-year period (1984–1996) [107]. In their study group in 435 (93%) child abuse could be confirmed, in 51 (11.7%) of them chart reviews showed enough evidence that should have led to a correct diagnosis at the first presentation. In this group 6 (12%) children died and 10 (20%) survived with handicap, which was severe in 4 cases.

#### 2.6.4.2 Specificity of Fractures, Sustained in Non-Accidental Circumstances

Although it is crucial for a responsible intervention, it is not always easy to differentiate between accidental and non-accidental circumstances, even if non-accidental circumstances are suspected [108]. According to Hobbs et al., non-accidental circumstances should be considered in case of [109, 110]:

- Multiple fractures in various stages of healing, even when no associated trauma is present, such as haematomas and (sub)cutaneous injuries.
- Damage to the epiphysis and metaphysis, possibly multiple as in the inflicted traumatic brain injury.
- Fractures of ribs (single or multiple), scapulae, and sternum.
- The presence of periosteal new bone formation.
- A skull fracture, with or without signs of intracranial trauma.
- Multiple and complicated skull fractures with a fracture width >3 mm.

Hobbs further stated that these fractures are more suspect than simple, uncomplicated fractures, shaft fractures of the long bones, and fractures of the clavicle and that fractures are more suspect when they occur simultaneously with other injuries, e.g. a simple fracture (e.g. of the humerus) combined with multiple unexplained haematomas [110].

In 1998, Kleinman presented an overview (Table 2.10) on the specificity of radiological findings regarding non-accidental trauma/inflicted fractures (child abuse) [111]. According to him, the highest specificity applied in infants. He also stated that non-accidental circumstances are likely when there is no explanation for the occurrence of fractures of average or low specificity or when the explanation does not correspond with the nature of the skeletal findings.

In a systematic review of the literature by Kemp et al., the predictive value of fractures as a sign of child abuse had been evaluated [112]. Other indications such as the child's age or

**Table 2.10** Specificity of skeletal injuries in child abuse

Specificity	Type of fracture/skeletal lesion
High specificity	Classic metaphyseal lesions (Metaphyseal corner fractures)
	Rib fractures, especially posterior
	Scapular fractures
	Spinous processes fractures
	Sternal fractures
Moderate specificity	Multiple fractures, specifically bilateral
	Fractures of different ages
	Epiphyseal separations
	Vertebral body fractures and subluxations
	Digital fractures
Common but low specificity	Complex skull fractures
	Subperiosteal new bone formation
	Clavicular fractures
	Long bone shaft fractures
	Linear skull fractures

Reprinted from Kleinman 1998 [111]. With permission

the injury that could lead to suspected child abuse were not taken into account. After a selection was made from 439 publications, 32 were analysed. Based on this systematic analysis, they concluded among others that rib fractures had the strongest correlation with non-accidental circumstances (child maltreatment). In 71% of cases (95% CI 42–91%) with rib fractures, the rib fractures were inflicted. They also found that none of the fractures was pathognomonic for child abuse. As such, the inflicted skeletal lesions may be similar to lesions found after an accident.

The determination whether a fracture was inflicted in a child not only depends on the characteristics of the fracture, as described in Sect. 2.4, or on the theoretical specificity of the fracture, as described in the foregoing text, but also on:

- The age and level of development of the child (Tables 2.11 and 2.12 and Chap. 13).
- The statements of the child, the parents, or the caregivers regarding the causing fracture.
- The theoretical reconstruction of the causing trauma, based on the known biomechanics.

When these are not compatible with the given statements of the child and/or the parents and/or caregivers about the causing trauma, non-accidental circumstances should be considered.

Performing the correct radiological examination and radiological dating of fractures is eminently important for an adequate diagnosis and protection at the moment that child abuse is suspected. Fractures as a result of violence can be found throughout the entire skeleton, are often present in multiple places, and may show various stages of

**Table 2.11** Overview of the general motor development at key ages [113–119]

Age	Skill	General motor development
4 weeks	Control muscles of the eye	Positive head lag
16 weeks	Head balance	Stable head balance Symmetric posture
28 weeks	Grip and manual manipulation	Sits and leans forward supported on the hands Stable stance when supported Asymmetric neck reflex disappears (22–26 weeks)
40 weeks	Control trunk and fingers: sitting, crawling, and picking	Sits without support Crawls Pulls up to stance Grip reflex at the feet disappears (40 weeks–18 months)
52 weeks	Control of legs and feet: the child stands erect and starts exploring	Walks holding on to one hand Walks along an object (such as coffee table or settee)
18 months	Control of larynx function: words and word combinations	Walks independently Able to sit up independently
24 months	Control of bladder and bowel functions	Is capable of running Can play football
36 months	Speaks in sentences	Can stand on one leg Jumps from the bottom step of the stairs
48 months	Understands numbers and shapes	Hops well on one leg Jumps forward on both legs
60 months	Child ready for school and prepared to play with other children	Hops equally well on either leg

**Table 2.12** Windows of achievement for six gross motor milestones according to the World Health Organization [120]

Motor milestone	Box boundary (age in months)			
	Lower	95% CI	Upper	95% CI
Sitting without support	3.8	3.7–3.9	9.2	8.9–9.4
Sitting with assistance	4.8	4.7–5.0	11.4	11.2–11.7
Hand and knees crawling	5.2	5.0–5.3	13.5	13.1–13.9
Walking with assistance	6.0	5.8–6.1	13.7	13.4–14.1
Standing alone	6.9	6.8–7.1	16.9	16.4–17.4
Walking alone	8.2	8.0–8.4	17.6	17.1–18.0

healing on skeletal radiographs [92, 102, 121]. Since in cases of child abuse there is often a delay in seeking medical help, dating may be complicated by further loading of the fracture by movement, additional injuries, and renewed fractures. The more or less objective radiological dating (see Chap. 4) can spot inconsistencies regarding subjective dating, based on the medical history, and the explanation of the injury.

### 2.6.4.3 The Value of Haematomas in the Differential Diagnosis Between Accidental and Non-accidental Circumstances

The little that is known about the presence of haematomas in relation to fractures in children has been learned through fractures that were sustained in non-accidental circumstances (inflicted fractures). In court procedures, it is sometimes claimed that haematomas are sustained at the same time as fractures ('the force required to cause a fracture will in all likelihood also result in haematomas') and that the absence of haematomas is proof that it took only very little force to break the bone and, as such, that the fracture must be due to disorders with an increased risk for fracturing, e.g. a metabolic disorder or from osteogenesis imperfecta. This opinion is based on one publication, in which this hypothesis was described, and is repeated regularly in court procedures, still without any evidence (see also Chaps. 15 and 16) [122, 123].

There is even ample evidence of the contrary. Mathew et al. conducted a prospective study into the presence of haematomas around the location of the fracture in 88 children that showed no signs of bone pathology with a total of 93 fractures (49 boys, 39 girls; age 12 months to 13 years and 11 months) [124]. All children were seen within 24 h after the fracture had been sustained. Only in eight fractures haematomas were found in the initial phase. No haematomas were found in fractures that showed no dislocation or in fractures that were well covered by soft tissue. In 13 other fractures, haematomas appeared within 24 h after hospitalization. Ultimately, 25 (28%) fractures were accompanied by haematomas 1 week after the fracture was sustained. According to Mathew et al., it is impossible to distinguish between fractures that are the result of bone disease and fractures resulting from child abuse based on the presence or absence of haematomas. It appears that in acutely sustained fractures in children, local haematomas are less common than one would expect; therefore, based on the absence of haematomas, non-accidental circumstances should never be excluded. Starling et al. also did not find any relation between fractures and the presence of haematomas [125]. After skull fractures had been excluded, it appeared that less than 10% of children had fracture-related haematomas. Peters et al. found that fractured bones that were most frequently associated with bruising were skull bones. The presence of bruising near the fracture site was uncommon in fractures of the extremities or the rib [126]. Valvano et al. found that the presence or absence of bruising was not useful in differentiating between inflicted and accidental fractures [127].

### 2.6.4.4 Perpetrators and Victims

Starling et al. were the first to initiate a study into the specific characteristics of perpetrators who cause fractures in children [125]. They evaluated the data of 194 children (age: 0–13.9 years; median 6 months) with in total 630 fractures. The

median number of fractures per patient was 2 and the maximum was 31. In 153 children (79%), the perpetrator could be identified. Nearly 68% of perpetrators were male. Of all known perpetrators, 45% appeared to be the biological father.

Furthermore, there appeared to be a significant difference ( $p = 0.003$ ) between the median age of the children who had been abused by a male (4.5 months) and by a female perpetrator (10 months). In 44 of the 194 children, the primary injury was non-accidental skull-/brain trauma. Since it is not known whether the age of victims of non-accidental skull-/brain trauma differs from that of children with other non-accidental fractures, further study was done after the children with non-accidental skull/brain trauma were excluded. However, this analysis still showed a significant difference ( $p = 0.004$ ) between the median age of children abused by a male (5 months) or a female perpetrator (12 months).

### 2.6.5 Fractures After Birth: Other Circumstances

Fractures that cannot be classified as classical accidental or non-accidental fractures are fractures that are due to, e.g. medical procedures (Sect. 13.4.2), habit disorders (Sect. 13.3.1), or sports activities (e.g. Sect. 13.5.2).

## References

1. Lyons RA, Delahunty AM, Kraus D, Heaven M, McCabe M, Allen H, Nash P (1999) Children's fractures: a population based study. *Inj Prev* 5:129–132
2. Landin LA (1983) Fracture patterns in children. Analysis of 8,682 fractures with special reference to incidence, etiology and secular changes in a Swedish urban population 1950–1979. *Acta Orthop Scand Suppl* 202:1–109
3. Landin LA (1997) Epidemiology of children's fractures. *J Pediatr Orthop B* 6:79–83
4. Worlock P, Stower M (1986) Fracture patterns in Nottingham children. *J Pediatr Orthop* 6:656–660
5. Rennie L, Court-Brown CM, Mok JY, Beattie TF (2007) The epidemiology of fractures in children. *Injury* 38:913–922
6. Hedström EM, Svensson O, Bergström U, Michno P (2010) Epidemiology of fractures in children and adolescents. *Acta Orthop* 81:148–153
7. Mäyränpää MK, Mäkitie O, Kallio PE (2010) Decreasing incidence and changing pattern of childhood fractures: a population-based study. *J Bone Miner Res* 25:2752–2759
8. Naranje SM, Erali RA, Warner WC Jr, Sawyer JR, Kelly DM (2016) Epidemiology of pediatric fractures presenting to emergency departments in the United States. *J Pediatr Orthop* 36:e45–e48
9. Mathison DJ, Agrawal D (2010) An update on the epidemiology of pediatric fractures. *Pediatr Emerg Care* 26:594–603
10. Ran Shin M, Fleming M (2019) Pediatric fractures in developing bone. <https://now.aapmr.org/pediatric-fractures-in-developing-bone/>. Accessed 15 July 2022
11. Wilkins KE, Aroojis AJ (2001) The present status of children's fractures. In: Beaty JH, Kasser JM (eds) *Rockwood and Wilkins'*

- fractures in children. Lippincott Williams & Wilkins, Philadelphia, pp 3–20
12. Akbarnia BA, Campbell RM (1990) The role of the orthopedic surgeon in child abuse. In: Morrissy RT, Winter RB (eds) Lovell and winter's pediatric orthopaedics. Lippincott Williams & Wilkins, Philadelphia
  13. Merten DF, Radlowski MA, Leonidas JC (1983) The abused child: a radiological reappraisal. *Radiology* 146:377–381
  14. Cadzow SP, Armstrong KL (2000) Rib fractures in infants: red alert! The clinical features, investigations and child protection outcomes. *J Paediatr Child Health* 36:322–326
  15. Rang MC, Willis RB (1977) Fractures and sprains. *Pediatr Clin N Am* 24:749–773
  16. Pierce MC, Bertocci GE (2006) Fractures resulting from inflicted trauma: assessing injury and history compatibility. *Clin Ped Emerg Med* 7:143–148
  17. van Rijn RR, Nijs HGT, Bilo RAC (2009) Evidence based imaging in non-CNS non-accidental injury. In: Medina LS, Applegate KE, Blackmore CC (eds) Evidence-based imaging in pediatrics. Springer, Cham, pp 177–191
  18. Keats TE, Anderson MW (2012) Atlas of normal roentgen variants which may simulate disease. Saunders, Philadelphia
  19. Bolander S (2019) A systematic approach to describing fractures. *JAAPA* 32:23–29
  20. Bell DJ, Gaillard F (2019) Fracture. <https://radiopaedia.org/articles/fracture-1?lang=us>. Accessed 18 Nov 2021
  21. Meinberg EG, Agel J, Roberts CS, Karam MD, Kellam JF (2018) Fracture and dislocation classification compendium-2018. *J Orthop Trauma* 32(Suppl. 1):S1–S170
  22. Lloyd-Jones G (2019) Introduction to trauma X-ray: fracture mimics. [https://www.radiologymasterclass.co.uk/tutorials/musculoskeletal/trauma/trauma\\_x-ray\\_start](https://www.radiologymasterclass.co.uk/tutorials/musculoskeletal/trauma/trauma_x-ray_start). Accessed 18 Nov 2021
  23. Murphy A, Hacking C (2019) Describing a fracture (an approach). <https://radiopaedia.org/articles/describing-a-fracture-an-approach?lang=us>. Accessed 18 Nov 2021
  24. Lewis WH (1918) Part II osteology. In: Lewis WH (ed) Gray's anatomy of the human body
  25. Jones J (2020) Bones types. <https://radiopaedia.org/articles/bones-types>. Accessed 18 Nov 2021
  26. Mulligan EP (2012) Lower leg, ankle, and foot rehabilitation. In: Andrews JR, Harrelson GL, Wilk KE (eds) Physical rehabilitation of the injured athlete. Elsevier, Philadelphia, pp 426–463
  27. Pinto DC, Love JC, Derrick SM, Wiersema JM, Donaruma-Kwoh M, Greeley CS (2015) A proposed scheme for classifying pediatric rib head fractures using case examples. *J Forensic Sci* 60:112–117
  28. Vaccaro AR, Lehman RA Jr, Hurlbert RJ, Anderson PA, Harris M, Hedlund R, Harrop J, Dvorak M, Wood K, Fehlings MG, Fisher C, Zeiller SC, Anderson DG, Bono CM, Stock GH, Brown AK, Kuklo T, Oner FC (2005) A new classification of thoracolumbar injuries: the importance of injury morphology, the integrity of the posterior ligamentous complex, and neurologic status. *Spine* 30:2325–2333
  29. Health Canada (2003) Injury surveillance in Canada: current realities, challenges. [http://www.injuryresearch.bc.ca/docs/3\\_20090910\\_100541Report%20HC%20Inj%20Surveillance%20in%20Can%20Aug%202003.pdf](http://www.injuryresearch.bc.ca/docs/3_20090910_100541Report%20HC%20Inj%20Surveillance%20in%20Can%20Aug%202003.pdf). Accessed 5 Aug 2021
  30. WHO Regional Office for Europe (2013) In: Sethi D, Bellis M, Hughes K, Gilbert R, Mitis G, Galea G (eds) European report on preventing child maltreatment
  31. National Institute for Health and Care Excellence (NICE) (2017) Osteoporosis: assessing the risk of fragility fracture. Clinical guideline [CG146]. <https://www.nice.org.uk/guidance/cg146>. Accessed 11 Aug 2021
  32. Jaimes C, Jimenez M, Shabshin N, Laor T, Jaramillo D (2012) Taking the stress out of evaluating stress injuries in children. *Radiographics* 32:537–555
  33. Sanderlin BW, Raspa RF (2003) Common stress fractures. *Am Fam Physician* 68:1527–1532
  34. American Academy of Orthopaedic Surgeons (AAOS) (2007) Stress fractures. <https://orthoinfo.aaos.org/en/diseases%2D%2Dconditions/stress-fractures/>. Accessed 18 Nov 2021
  35. DeWeber K (2017) Overview of stress fractures. <https://www.uptodate.com/contents/overview-of-stress-fractures>. Accessed 10 Aug 2021
  36. Griffiths AL (1952) Fatigue fracture of the fibula in childhood. *Arch Dis Child* 27:552–557
  37. Bedoya MA, Jaramillo D, Chauvin NA (2015) Overuse injuries in children. *Top Magn Reson Imaging* 24:67–81
  38. Shelat NH, El-Khoury GY (2016) Pediatric stress fractures: a pictorial essay. *Iowa Orthop J* 36:138–146
  39. Wu M, Fallon R, Heyworth BE (2016) Overuse injuries in the pediatric population. *Sports Med Arthrosc Rev* 24:150–158
  40. Devas MB (1963) Stress fractures in children. *J Bone Joint Surg Br* 45:528–541
  41. Torwalt CR, Balachandra AT, Youngson C, de Nanassy J (2002) Spontaneous fractures in the differential diagnosis of fractures in children. *J Forensic Sci* 47:1340–1344
  42. Canavese F, Samba A, Rousset M (2016) Pathological fractures in children: diagnosis and treatment options. *Orthop Traumatol Surg Res* 102:S149–S159
  43. Boyce AM, Gafni RI (2011) Approach to the child with fractures. *J Clin Endocrinol Metab* 96:1943–1952
  44. De Mattos CB, Binitie O, Dormans JP (2012) Pathological fractures in children. *Bone Joint Res* 1:272–280
  45. Altman DH, Smith RL (1960) Unrecognized trauma in infants and children. *J Bone Joint Surg Am* 42-a:407–413
  46. Mendelson KL (2005) Critical review of 'temporary brittle bone disease'. *Pediatr Radiol* 35:1036–1040
  47. Wick JY (2009) Spontaneous fracture: multiple causes. *Consult Pharm* 24:100–102, 105–108, 110–102
  48. Wong SC, Catto-Smith AG, Zacharin M (2014) Pathological fractures in paediatric patients with inflammatory bowel disease. *Eur J Pediatr* 173:141–151
  49. Greeley CS, Donaruma-Kwoh M, Vettimattam M, Lobo C, Williard C, Mazur L (2013) Fractures at diagnosis in infants and children with osteogenesis imperfecta. *J Pediatr Orthop* 33:32–36
  50. MacAusland WR (1972) Sprains, fractures, dislocations. In: Nardi GL, Zuidema GD (eds) Surgery, a concise guide to clinical practice. Little Brown, Boston, p 945
  51. Alexander E Jr, Davis CH Jr (1969) Intra-uterine fracture of the infant's skull. *J Neurosurg* 30:446–454
  52. Garza-Mercado R (1982) Intrauterine depressed skull fractures of the newborn. *Neurosurgery* 10:694–697
  53. Morgan JA, Marcus PS (2010) Prenatal diagnosis and management of intrauterine fracture. *Obstet Gynecol Surv* 65:249–259
  54. Veeravagu A, Azad TD, Jiang B, Edwards MSB (2018) Spontaneous intrauterine depressed skull fractures: report of 2 cases requiring neurosurgical intervention and literature review. *World Neurosurg* 110:256–262
  55. Barker TH (1857) On intrauterine fractures: with an illustrative case. *Br Med J* 2:806–809
  56. Brodhurst BE (1860) Cases of intra-uterine fracture with observations to show the analogy between fracture in utero and congenital distorsion
  57. Murray GCP (1857) Intrauterine fractures. *BMJ* s4-1:865

58. Smith RR (1913) Intrauterine fracture: report of a case and a review of the literature. *Surg Gynecol Obstet* 17:346–349
59. Snure H (1929) Intra-uterine fracture – case report and review of roentgenologic findings. *Radiology* 13:362–365
60. Dawson GR Jr (1949) Intra-uterine fractures of the tibia and fibula; report of a case with correction by osteotomy and plating. *J Bone Joint Surg Am* 31a:406–408
61. Dupuis O, Silveira R, Dupont C, Mottolose C, Kahn P, Dittmar A, Rudigoz RC (2005) Comparison of “instrument-associated” and “spontaneous” obstetric depressed skull fractures in a cohort of 68 neonates. *Am J Obstet Gynecol* 192:165–170
62. Alonso JA, Wright DM, Sochart DH (2005) Intrauterine femoral fracture diagnosed at birth – maternal abdominal trauma versus non-accidental injury. *Inj Extra* 36:432–433
63. Arioz DT, Koken GN, Koken R, Kose KC, Cevrioglu AS (2008) Isolated intrauterine femoral fracture in an otherwise normal fetus. *J Obstet Gynaecol Res* 34:92–94
64. Bailey BA (2010) Partner violence during pregnancy: prevalence, effects, screening, and management. *Int J Women's Health* 2:183–197
65. Cook J, Bewley S (2008) Acknowledging a persistent truth: domestic violence in pregnancy. *J R Soc Med* 101:358–363
66. Pearsall AWT, Larkin JJ, Raasch W (1992) Intrauterine femur fracture. *Orthopedics* 15:947–950
67. Yu M, Xu D, Zhang A, Shen J (2018) Spontaneous fetal femoral fracture: a case report and literature review. *J Int Med Res* 46:1282–1287
68. Freedman M, Gamble J, Lewis C (1982) Intrauterine fracture simulating a unilateral clavicular pseudarthrosis. *J Can Assoc Radiol* 33:37–38
69. Heath PM (1912) Intra-uterine fracture of tibia and fibula, with absorption of bone. *Proc R Soc Med* 5:10–12
70. Hawthorne ES (1903) Fractured clavicle with ossific union in utero. *Lancet* 162:315
71. Nicole R (1954) Traumatische intrauterine Unterschenkelfraktur; Beitrag zur Frage der sog. Congenitalen Unterschenkel-Pseudarthrose [Traumatic intrauterine fracture of the lower leg; a contribution to the problem of so-called pseudarthrosis of lower-leg]. *Bibl Paediatr* 58:743–755
72. Scheier M, Peter M, Hager C, Lang T, Barvinek A, Marth C (2010) Spontaneous isolated midtrimester fracture of tibia and fibula in a normal fetus with in utero healing and good long-term outcome. *Fetal Diagn Ther* 28:58–60
73. Weinberg L, Wyatt JP, Busuttill A (2001) Traumatic intrauterine fetal spinal fracture following seat belt use: a case report. *J Trauma* 51:1195–1196
74. Dennis NR, Fairhurst J, Moore IE (1995) Lethal syndrome of slender bones, intrauterine fractures, characteristics facial appearance, and cataracts, resembling Hallermann-Streiff syndrome in two sibs. *Am J Med Genet* 59:517–520
75. Jain A, Kumar Jha B, Chopra A (2019) Case report: type 0 spinal muscular atrophy associated with fractures at birth. *J Clin Neonatol* 8:125–127
76. Lacson AG, Donaldson G, Barness EG, Ranells JD, Pomerance HH (2002) Infant with high arched palate, bell-shaped chest, joint contractures, and intrauterine fractures. *Pediatr Pathol Mol Med* 21:569–584
77. Marchesoni M, Helfer A (1955) An unusual case of multiple intrauterine Su di un raro Caso di fratture fetali multiple endouterine per osteogenesi imperfetta tipo Vrölik [fetal fractures caused by Vrölik's type of osteogenesis imperfecta]. *Ann Ostet Ginecol* 77:585–594
78. Roszbach HC, Dalence C, Wynn T, Tebbi C (2006) Faisalabad histiocytosis mimics Rosai-Dorfman disease: brothers with lymphadenopathy, intrauterine fractures, short stature, and sensorineural deafness. *Pediatr Blood Cancer* 47:629–632
79. Jaarsma AS (2007) Botbreuken bij pasgeborenen [Fractures in neonates]. *Patient Care* 34:9–12
80. Morris S, Cassidy N, Stephens M, McCormack D, McManus F (2002) Birth-associated femoral fractures: incidence and outcome. *J Pediatr Orthop* 22:27–30
81. Simonson C, Barlow P, Dehennin N, Spheh M, Toppet V, Murillo D, Rozenberg S (2007) Neonatal complications of vacuum-assisted delivery. *Obstet Gynecol* 109:626–633
82. Joseph PR, Rosenfeld W (1990) Clavicular fractures in neonates. *Am J Dis Child* 144:165–167
83. Kogutt MS, Swischuk LE, Fagan CJ (1974) Patterns of injury and significance of uncommon fractures in the battered child syndrome. *Am J Roentgenol Radium Therapy Nucl Med* 121:143–149
84. Cumming WA (1979) Neonatal skeletal fractures. Birth trauma or child abuse? *J Can Assoc Radiol* 30:30–33
85. Walters MM, Forbes PW, Buonomo C, Kleinman PK (2014) Healing patterns of clavicular birth injuries as a guide to fracture dating in cases of possible infant abuse. *Pediatr Radiol* 44:1224–1229
86. Fadell M, Miller A, Trefan L, Weinman J, Stewart J, Hayes K, Maguire S (2017) Radiological features of healing in newborn clavicular fractures. *Eur Radiol* 27:2180–2187
87. Rubin A (1964) Birth injuries: incidence, mechanisms and end results. *Obstet Gynecol* 23:218–221
88. Camus M, Lefebvre G, Veron P, Darbois Y (1985) Traumatismes obstétricaux du nouveau-né. Enquête rétrospective à propos de 20409 naissances [Obstetrical injuries of the newborn infant. Retrospective study apropos of 20,409 births]. *J Gynecol Obstet Biol Reprod (Paris)* 14:1033–1043
89. Bhat BV, Kumar A, Oumachigui A (1994) Bone injuries during delivery. *Indian J Pediatr* 61:401–405
90. Groenendaal F, Hukkelhoven C (2007) Botbreuken bij voldragen pasgeborenen [Fractures in full-term neonates]. *Ned Tijdschr Geneesk* 151:424
91. van Rijn RR, Bilo RA, Robben SG (2009) Birth-related mid-posterior rib fractures in neonates: a report of three cases (and a possible fourth case) and a review of the literature. *Pediatr Radiol* 39:30–34
92. Worlock P, Stower M, Barbor P (1986) Patterns of fractures in accidental and non-accidental injury in children: a comparative study. *BMJ* 293:100–102
93. Cramer K (1996) Orthopedic aspects of child abuse. *Pediatr Clin N Am* 43:1035–1051
94. McMahan P, Grossman W, Gaffney M, Stanitski C (1995) Soft-tissue injury as an indication of child abuse. *J Bone Joint Surg Am* 77:1179–1183
95. Loder RT, Bookout C (1991) Fracture patterns in battered children. *J Orthop Trauma* 5:428–433
96. Sinal SH, Stewart CD (1998) Physical abuse of children: a review for orthopedic surgeons. *J South Orthop Assoc* 7:264–276
97. Holter JC, Friedman SB (1968) Child abuse: early case finding in the emergency department. *Pediatrics* 42:128–138
98. Hyden PW, Gallagher TA (1992) Child abuse intervention in the emergency room. *Pediatr Clin N Am* 39:1053–1081
99. Lucas DR, Wezner KC, Milner JS, McCanne TR, Harris IN, Monroe-Posey C, Nelson JP (2002) Victim, perpetrator, family, and incident characteristics of infant and child homicide in the United States Air Force. *Child Abuse Negl* 26:167–186

100. Akbarnia B, Torg JS, Kirkpatrick J, Sussman S (1974) Manifestations of the battered-child syndrome. *J Bone Joint Surg Am* 56:1159–1166
101. King J, Diefendorf D, Apthorp J, Negrete VF, Carlson M (1988) Analysis of 429 fractures in 189 battered children. *J Pediatr Orthop* 8:585–589
102. Leventhal JM, Thomas SA, Rosenfield NS, Markowitz RI (1993) Fractures in young children. Distinguishing child abuse from unintentional injuries. *Am J Dis Child* 147:87–92
103. Skellern CY, Wood DO, Murphy A, Crawford M (2000) Non-accidental fractures in infants: risk of further abuse. *J Paediatr Child Health* 36:590–592
104. Barsness KA, Cha ES, Bensard DD, Calkins CM, Partrick DA, Karrer FM, Strain JD (2003) The positive predictive value of rib fractures as an indicator of nonaccidental trauma in children. *J Trauma* 54:1107–1110
105. Banaszkiwicz PA, Scotland TR, Myerscough EJ (2002) Fractures in children younger than age 1 year: importance of collaboration with child protection services. *J Pediatr Orthop* 22:740–744
106. Oral R, Blum KL, Johnson C (2003) Fractures in young children: are physicians in the emergency department and orthopedic clinics adequately screening for possible abuse? *Pediatr Emerg Care* 19:148–153
107. Carty HM, Pierce A (2002) Non-accidental injury: a retrospective analysis of a large cohort. *Eur Radiol* 12:2919–2925
108. Taitz J, Moran K, O'Meara M (2004) Long bone fractures in children under 3 years of age: is abuse being missed in emergency department presentations? *J Paediatr Child Health* 40:170–174
109. Hobbs CJ, Hanks HGI, Wynne JM (1993) Child abuse and neglect – a clinician's handbook. Churchill Livingstone, London
110. Hobbs CJ (1989) ABC of child abuse fractures. *BMJ* 298:1015–1018
111. Kleinman PK (1998) Skelet trauma: general considerations. In: Kleinman PK (ed) Diagnostic imaging of child abuse. Mosby, St. Louis, pp 8–25
112. Kemp AM, Dunstan F, Harrison S, Morris S, Mann M, Rolfe K, Datta S, Thomas DP, Sibert JR, Maguire S (2008) Patterns of skeletal fractures in child abuse: systematic review. *BMJ* 337:a1518
113. Gesell A, Amatruda CS (1964) Developmental diagnosis. Hoever Medical Division, Harper & Row Publishers, New York
114. Egan DF, Illingworth RS, MacKeith RC (1969) Developmental screening. 0–5 years. In: Gardiner P, MacKeith R, Smith V (eds) Aspects of developmental and paediatric ophthalmology. S.I.M.P. with Heinemann Medical, London
115. Flehmig I (2007) Normale Entwicklung des Säuglings und ihre Abweichungen: Früherkennung und Frühbehandlung. Thieme Verlag, Stuttgart
116. Illingworth RS (1988) Basic developmental screening: 0–4 years. Wiley-Blackwell, Oxford
117. Illingworth RS (1983) Development of the infant and young child: Normal and abnormal. Churchill Livingstone, Edinburgh
118. Knobloch H, Pasamanick B (1974) Gesell and Amatruda's developmental diagnosis: the evaluation and management of normal and abnormal neuropsychologic development in infancy and early childhood. Harper & Row
119. Bilo RAC, Voorhoeve HWA (2017) Kind in ontwikkeling – een handreiking bij de observatie van jonge kinderen. Elsevier Tijdstroom, Maarssen
120. WHO Multicentre Growth Reference Study Group (2006) WHO Motor Development Study: windows of achievement for six gross motor development milestones. *Acta Paediatr Suppl* 450:86–95
121. Duhaime AC, Alario AJ, Lewander WJ, Schut L, Sutton LN, Seidl TS, Nudelman S, Budenz D, Hertle R, Tsiaras W et al (1992) Head injury in very young children: mechanisms, injury types, and ophthalmologic findings in 100 hospitalized patients younger than 2 years of age. *Pediatrics* 90:179–185
122. Paterson CR (1987) Child abuse or copper deficiency? *Br Med J (Clin Res Ed)* 295:213–214
123. Taitz LS (1991) Child abuse and metabolic bone disease: are they often confused? *BMJ* 302:1244
124. Mathew MO, Ramamohan N, Benet GC (1998) Importance of bruising associated with paediatric fractures: prospective observational study. *BMJ* 317:1117–1118
125. Starling SP, Sirotak AP, Heisler KW, Barnes-Eley ML (2007) Inflicted skeletal trauma: the relationship of perpetrators to their victims. *Child Abuse Negl* 31:993–999
126. Peters ML, Starling SP, Barnes-Eley ML, Heisler KW (2008) The presence of bruising associated with fractures. *Arch Pediatr Adolesc Med* 162:877–881
127. Valvano TJ, Binns HJ, Flaherty EG, Leonhardt DE (2009) Does bruising help determine which fractures are caused by abuse? *Child Maltreat* 14:376–381