

**Document Version**

Final published version

**Citation (APA)**

Rauwers, A. W., Troelstra, A., Fluit, A. C., Wissink, C., Loeve, A. J., Vleggaar, F. P., Bruno, M. J., Vos, M. C., Bode, L. G., & Monkelbaan, J. F. (2019). Independent root-cause analysis of contributing factors, including dismantling of 2 duodenoscopes, to investigate an outbreak of multidrug-resistant *Klebsiella pneumoniae*. *Gastrointestinal Endoscopy*, *90*(5), 793-804. <https://doi.org/10.1016/j.gie.2019.05.016>

**Important note**

To cite this publication, please use the final published version (if applicable).  
Please check the document version above.

**Copyright**

In case the licence states "Dutch Copyright Act (Article 25fa)", this publication was made available Green Open Access via the TU Delft Institutional Repository pursuant to Dutch Copyright Act (Article 25fa, the Taverne amendment). This provision does not affect copyright ownership.  
Unless copyright is transferred by contract or statute, it remains with the copyright holder.

**Sharing and reuse**

Other than for strictly personal use, it is not permitted to download, forward or distribute the text or part of it, without the consent of the author(s) and/or copyright holder(s), unless the work is under an open content license such as Creative Commons.

**Takedown policy**

Please contact us and provide details if you believe this document breaches copyrights.  
We will remove access to the work immediately and investigate your claim.

***Green Open Access added to TU Delft Institutional Repository***

***'You share, we take care!' - Taverne project***

**<https://www.openaccess.nl/en/you-share-we-take-care>**

Otherwise as indicated in the copyright section: the publisher is the copyright holder of this work and the author uses the Dutch legislation to make this work public.



# Independent root-cause analysis of contributing factors, including dismantling of 2 duodenoscopes, to investigate an outbreak of multidrug-resistant *Klebsiella pneumoniae*

Arjan W. Rauwers, MD,<sup>1</sup> Annet Troelstra, MD, PhD,<sup>2</sup> Ad C. Fluit, MD, PhD,<sup>2</sup> Camiel Wissink,<sup>2</sup> Arjo J. Loeve, PhD, Eng,<sup>3,4</sup> Frank P. Vleggaar, MD, PhD,<sup>5</sup> Marco J. Bruno, MD, PhD,<sup>1</sup> Margreet C. Vos, MD, PhD,<sup>6</sup> Lonneke G. Bode, MD, PhD,<sup>2,6</sup> Jan F. Monkelbaan, MD<sup>5</sup>

Rotterdam, Utrecht, Delft, Amsterdam, The Netherlands

**Background and Aims:** Worldwide, an increasing number of duodenoscope-associated outbreaks are reported. The high prevalence rate of contaminated duodenoscopes puts patients undergoing ERCP at risk of exogenous transmission of microorganisms. The contributing factors of the duodenoscope design to contamination are not well understood. This article reports on the investigation after the outbreak of a multidrug-resistant *Klebsiella pneumoniae* (MRKP) related to 2 Olympus TJF-Q180V duodenoscopes.

**Methods:** We conducted a contact patient screening and microbiologic laboratory database search. Reprocessing procedures were audited, and both duodenoscopes were fully dismantled to evaluate all potential contamination factors. Outcomes were reviewed by an experienced independent expert.

**Results:** In total, 102 patients who had undergone an ERCP procedure from January to August 2015 were invited for screening. Cultures were available of 81 patients, yielding 27 MRKP-infected or -colonized patients. Ten patients developed an MRKP-related active infection. The 2 duodenoscopes had attack rates (the number of infected or colonized cases/number of exposed persons) of 35% (17/49) and 29% (7/24), respectively. Identical MRKP isolates were cultured from channel flushes of both duodenoscopes. The review revealed 4 major abnormalities: miscommunication about reprocessing, undetected damaged parts, inadequate repair of duodenoscope damage, and duodenoscope design abnormalities, including the forceps elevator, elevator lever, and instrumentation port sealing.

**Conclusions:** Outbreaks are associated with a combination of factors, including duodenoscope design issues, repair issues, improper cleaning, and systemic monitoring of contamination. To eliminate future duodenoscope-associated infections, a multipronged approach is required, including clear communication by all parties involved, a reliable servicing market, stringent surveillance measures, and eventually new duodenoscope designs and reprocessing procedures with a larger margin of safety. (Gastrointest Endosc 2019;90:793-804.)

*Abbreviations:* ESBL, extended-spectrum  $\beta$ -lactamase; IFU, instructions for use; ISO, independent service organization; MRKP, multidrug-resistant *Klebsiella pneumoniae*; UMCU, University Medical Center Utrecht.

**DISCLOSURE:** The following authors disclosed financial relationships relevant to this publication: F. P. Vleggaar: Consultant for and research grant recipient from Boston Scientific. M. J. Bruno: Consultant for 3M, Boston Scientific, and Cook Medical; speaker for Boston Scientific and Cook Medical; grant recipient from 3M, Boston Scientific, Cook Medical, and Pentax Medical. M. C. Vos: Grant recipient from 3M, Pentax Medical, and IMS Innovations. All other authors disclosed no financial relationships relevant to this publication.

Copyright © 2019 by the American Society for Gastrointestinal Endoscopy 0016-5107/\$36.00

<https://doi.org/10.1016/j.gie.2019.05.016>

Received December 27, 2018. Accepted May 5, 2019.

Current affiliations: Department of Gastroenterology and Hepatology (1), Department of Medical Microbiology and Infectious Diseases (6), Erasmus MC University Medical Center, Rotterdam, The Netherlands; Department of Medical Microbiology (2), Department of Gastroenterology and Hepatology (5), University Medical Center Utrecht, Utrecht, The Netherlands; Department of Biomechanical Engineering, Faculty of Mechanical, Maritime and Materials Engineering, Delft University of Technology, Delft, The Netherlands (3), Co van Ledden Hulsebosch Center for Forensic Science and Medicine, Amsterdam, The Netherlands (4).

Reprint requests: Col (Ret) Jan F. Monkelbaan, MD, Department of Gastroenterology and Hepatology, University Medical Center Utrecht, UMCU post number F.02.694, PO Box 85500, 3508 GA Utrecht, The Netherlands.

If you would like to chat with an author of this article, you may contact Dr Monkelbaan at [J.F.Monkelbaan@umcutrecht.nl](mailto:J.F.Monkelbaan@umcutrecht.nl).

In recent years a rising number of outbreaks of infectious multidrug-resistant organisms caused by contaminated duodenoscopes have been reported worldwide, with at least 400 patient infections and at least 20 deaths.<sup>1-3</sup> Duodenoscopes are mostly used for therapeutic ERCP procedures. At 1% to 4%, the post-ERCP infection rate is higher compared with regular GI endoscopic procedures.<sup>4-7</sup> This rate is for the most part rightly attributed to endogenous infections and inherent to the ERCP procedure. However, unique ERCP-related factors, including design issues, may possibly contribute to exogenous transmission through contaminated duodenoscopes.

The total number of outbreaks may be underestimated: Registration of outbreaks is imperfect, detected outbreaks may not always be reported, and outbreaks in smaller centers and in particular transmissions of non-multidrug-resistant organisms can remain unnoticed and might therefore not be reported as outbreaks.<sup>1,2,8</sup> The published outbreaks could only be detected and retrospectively traced because of the distinct features of the causative microorganisms, that is, multidrug-resistant organisms.<sup>1,2</sup> This was almost only possible in large academic referral centers with the necessary microbiologic laboratory alert system capabilities.<sup>1,2</sup> Studies show duodenoscope contamination incidences ranging from 1% to 35%.<sup>9-14</sup> A recent nationwide Dutch study by our group showed that 15% of the patient-ready duodenoscopes were contaminated with GI or oral flora,<sup>15</sup> indicating that patients undergoing ERCP have been exposed to contaminated equipment with risk of transmission.

Reprocessing, which is used to prevent transmission of microorganisms, does not always offer a guaranteed adequate decontamination of duodenoscopes.<sup>15</sup> During endoscopic procedures, duodenoscopes can be contaminated with a microbiologic load up to 7 to 10 log<sub>10</sub>.<sup>16-19</sup> Reprocessing, consisting of flushing, cleaning, high-level disinfection, and drying, reduces at maximum 6 to 12 log<sub>10</sub>.<sup>16-19</sup> This margin of safety leaves no room for error. However, reprocessing is error-prone,<sup>20-22</sup> because the essential step of meticulous cleaning must be performed manually. Furthermore, duodenoscopes are more difficult to reprocess compared with other endoscopes because of their complex design.<sup>16,23</sup> This consists of a side-viewing tip with a forceps elevator and elevator wire channel that is sealed off in the current duodenoscope types from Olympus, Pentax, and Fujifilm. Contributing to persistent contamination, the complex design may explain why outbreaks still might occur even when reprocessing is performed exactly according the manufacturers' instructions for use (IFU), as was reported in other cases.<sup>24,25</sup>

The mechanisms behind the duodenoscope design contributing to contamination are not well understood. To the best of our knowledge, only 1 dismantling of a contaminated Olympus TJF-Q180V duodenoscope was investigated by an independent expert.<sup>26,27</sup> One conclusion

of this investigation was that the specific design, including a fixed distal cap, hampered adequate cleaning.<sup>26,27</sup> This led to design modifications and worldwide recall, including 4400 duodenoscopes in the United States.<sup>28</sup> Recent borescope studies have shown that GI endoscopes, including duodenoscopes, frequently have damaged working channels,<sup>29-31</sup> possibly impeding adequate removal of organic debris. Dismantling of outbreak-associated duodenoscopes would improve our understanding of duodenoscope factors and may eventually lead to safer endoscopic procedures.

Identification of 2 patients on the same ward colonized with a multidrug-resistant *Klebsiella pneumoniae* (MRKP) infection led to the discovery that 2 duodenoscopes had been the source for 27 colonized or infected patients for at least 8 months. This article reports on the outbreak investigation, including an extensive reprocessing audit, full dismantling of both duodenoscopes, and review of these results by the same independent expert as the previously mentioned report, with the aim to identify all factors contributing to the persistent contamination of the duodenoscopes.

## METHODS

### Setting

The University Medical Center Utrecht (UMCU) is a 1042-bed, tertiary academic center in The Netherlands performing 300 ERCP procedures yearly. At the time of the detection of the outbreak (July 2015), 2 Olympus TJF-Q180V (Zoeterwoude, The Netherlands) duodenoscopes (A and B) and 2 older Olympus TJF-160VR models (C and D) were being used. Maintenance and repairs were performed by a single independent service organization (ISO). Duodenoscope A (3.9 years; 571 procedures) had been repaired in May 2014 and twice in May 2015. Duodenoscope B (1.9 years; 287 procedures) had been repaired in January and March 2015. From 3 years after commissioning, duodenoscopes C (5.9 years) and D (5 years) both were repaired 6 times. Their number of procedures was not registered from the date of commissioning.

### Outbreak investigation

In July 2015, MRKP isolates were detected in clinical cultures from 2 patients admitted at the same surgical ward on different days. These *K pneumoniae* were resistant to third-generation cephalosporins (because of the production of extended-spectrum  $\beta$ -lactamase [ESBL] and/or AmpC  $\beta$ -lactamase), intermediately susceptible to meropenem, and resistant to colistin.

A contact investigation was initiated to assess possible transmission of identical MRKP, consisting of screening of patients and a microbiological laboratory database search. Contact patients (n = 72) were defined as index

patients' roommates and those patients hospitalized at the same surgical ward for at least 14 days during the index patients' admission period. Contact patients were asked to take rectal swabs on 5 consecutive days to screen for multidrug-resistant gram-negative bacteria. Additionally, the laboratory database was searched using the following criteria: cultures from January 1, 2015, *K pneumoniae* identified by matrix-assisted laser desorption/ionization–time of flight mass spectrometry, ESBL positive or not interpretable, and resistance to cefoxitin and colistin. This laboratory database search identified 15 patients with phenotypically identical MRKP isolates, analyzed using DiversiLab (bioMérieux, Marcy-l'Étoile, France). Six of these 15 patients did not have a classic (same time, same place) epidemiologic link to the index cases, but review of their medical records revealed that all patients had undergone an ERCP procedure with duodenoscopes A or B. Therefore, 24 days after the investigation had started, duodenoscopes A and B were quarantined, and subsequent ERCP procedures were performed using duodenoscopes C and D. Cultures taken from duodenoscopes A and B showed persistent contamination with MRKP in both duodenoscopes. Duodenoscope C was also temporarily quarantined because of contamination but was returned to service after culture results were negative after a second reprocessing cycle.

Screening of contact patients was expanded to all 102 patients who underwent an ERCP procedure at the UMCU in 2015. A case was defined as a patient who was colonized or infected with the MRKP outbreak strain, identical to the index isolates using DiversiLab, identified from a clinical or screening culture *and* who underwent an ERCP procedure with duodenoscopes A or B. After finishing the contact investigation in November 2015, the outbreak date range was set to January to August 2015. A patient colonized with MRKP, unknown at that time, may have contaminated duodenoscope A in the fall of 2014. Expansion of the contact investigation was not deemed necessary because a laboratory database search over 2014 did not yield extra MRKP cases. Furthermore, screening of additional patients who had undergone an ERCP more than a year ago was considered ineffective, because spontaneous decolonization may have occurred.

### Sampling, culture, and molecular typing methods

At first only the quarantined duodenoscopes A and B were sampled, but eventually all 4 duodenoscopes and 4 Olympus ETD3 automated endoscope reproprocessors were sampled using a uniform sampling protocol according to the Dutch guideline.<sup>32</sup> Because of positive culture results, duodenoscopes A, B, and C were reprocessed and sampled a second time. Placed on a sterile surface, 3 to 4 sites per duodenoscope were sampled. The 3 common sample sites were flush of the suction channel,

flush of the biopsy channel, and swab of the distal tip, including the forceps elevator. The unsealed elevator wire channels of duodenoscopes C and D were flushed as well. Channels were flushed with sterile .9% NaCl fluid, of which at least 20 mL was collected at the distal tip. Distal tips were sampled with Tubed Sterile Dryswabs (MWE, Wiltshire, England). During the second sampling, smaller Pernal Dryswabs (MWE, Wiltshire, England, UK) were used to reach all crevices.

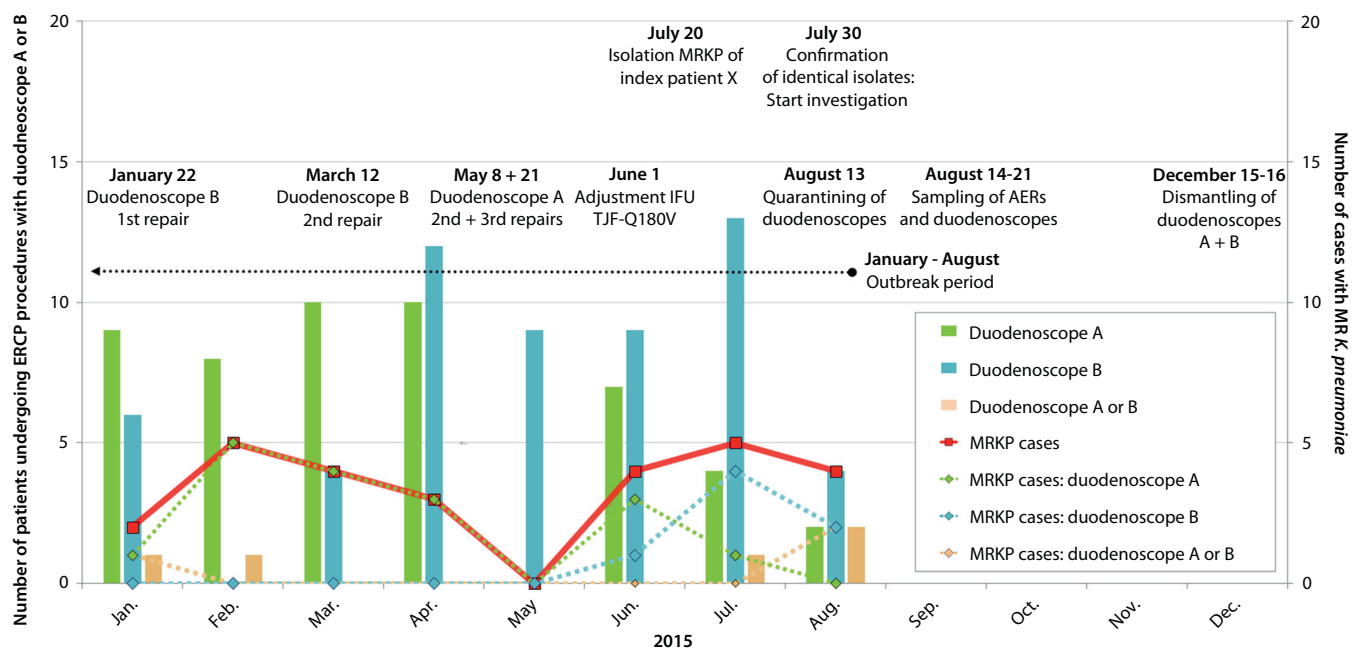
Before dismantling, duodenoscopes A and B were sampled again. The distal tip was sampled using Pernal Dryswabs (MWE, Wiltshire, England) and BW-412T (Olympus, Zoeterwoude, The Netherlands) and MAJ-1888 (Olympus, Zoeterwoude, The Netherlands) cleaning brushes (Olympus, Zoeterwoude, The Netherlands); the entrance of the biopsy channel was sampled with the BW-412T brush. All channels were flushed; of each channel at least 100 mL was collected at the distal tip. All separate dismantled parts were sampled with Pernal Dryswabs.

Channel flushes were filtrated over a .45- $\mu$ m filter using a Sentino Microbiology pump (Pall, Medemblik, The Netherlands), after which the residue was fixed on R2A-agar. Swabs were inoculated on blood agar. Samples were incubated for 72 hours at 35° to 37°C. Culture results were presented in colony-forming units/20 mL per microorganism. *K pneumoniae* isolates were typed using DiversiLab, a polymerase chain reaction fingerprinting system using repetitive sequences, and with next-generation sequencing.

### Other investigations

**External review.** The outbreak team decided in cooperation with Olympus to invite an experienced independent expert of the Delft University of Technology, who also reviewed the previous outbreak in the Netherlands,<sup>23,26,27</sup> to assess all potential factors contributing to the outbreak. This included an extensive audit and dismantling of both TJF-Q180V duodenoscopes A and B by dedicated Olympus technicians at Olympus (Zoeterwoude, The Netherlands) under supervision of the independent expert. An UMCU infection control practitioner specialized in flexible endoscopes audited the reprocessing procedure. Reprocessing was performed according to the at-that-time current IFU and Dutch guidelines.<sup>32</sup> Traceability of the duodenoscope was guaranteed using Hygienetracker (Star Medical Systems, Montfoort, The Netherlands).

**Duodenoscope dismantling.** All procedures were documented, filmed, and photographed by the independent expert and conducted in the presence of Olympus and UMCU representatives. At the UMCU, first the duodenoscopes were reprocessed and dried according to the IFU, except for the use of the manual cleaner agent Neodisher Mediclean Forte (Dr. Weigert, Assen, The Netherlands). Second, at Olympus, the duodenoscope forceps elevator area and channels were visually inspected



**Figure 1.** Timeline of the outbreak. *Green and blue bars*, number of patients who have undergone an ERCP procedure with duodenoscope A or B, respectively. Follow-up procedures with the same duodenoscope were excluded; *pink bar*, number of patients who have undergone a procedure with duodenoscope A or B; *solid red line*, all MRKP cases retrospectively detected by clinical or screening cultures; *dashed green line*, all cases with MRKP treated with duodenoscope A; *dashed blue line*, all cases with MRKP treated with duodenoscope B; *dashed pink line*, all cases with MRKP treated with a TJF-Q180V duodenoscope, either A or B. The outbreak period was set from January to August 2015. *MR*, Multidrug-resistant; *MRKP*, multidrug-resistant *K pneumoniae*.

using a small-diameter Olympus IPLEX-TX borescope. Finally, the distal tip, biopsy channel, instrument channel port, air/water channels, and the control section were dismantled using sterilized instruments on a sterile surface. Each part was inspected, sampled, and then cleaned with ethanol before removing it from the duodenoscope to prevent cross-contamination or dislocation of traces.

## RESULTS

### Outbreak investigation

The outbreak investigation yielded culture results from 81 patients of the 102 contact patients. Eight patients refused to participate or did not respond to the request for screening, and 13 patients died in 2015 without any screening or clinical cultures available. An independent committee of medical experts reviewed the medical charts and considered their deaths not to be related to a possible colonization or infection with the outbreak strain. The epidemic curve is shown in Figure 1. In total, 27 cases were identified: 1 of the 2 index patients had undergone an ERCP, 15 patients were identified as cases by the laboratory database search, and 11 patients were identified as cases by contact screening. ERCP characteristics, culture source, and culture indication of each patient are shown in Table 1. At least 10 cases developed an MRKP-related active infection: 6 cases at

presentation (5 sepsis; 1 cholangitis) and 4 sepsis cases at a later moment. At first, only duodenoscope A infected patients with an attack rate (number of infected or colonized cases/number of exposed persons) of 35% (17/49 patients). After 6 months, duodenoscope B (attack rate, 29%; 7/24 patients) was also an MRKP vector. Three patients who underwent ERCP procedures with duodenoscope A first and duodenoscope B later may have been the possible link between both duodenoscopes.

Culturing of duodenoscopes A and B showed persistent contamination of the channels with identical MRKP isolates (Table 2). The following microorganisms were also cultured: ESBL-producing *Escherichia coli* and *Citrobacter freundii*, *Enterobacter cloacae* complex, *Pseudomonas aeruginosa*, *Klebsiella oxytoca*, and *Stenotrophomonas maltophilia*. Although no *K pneumoniae* was found in duodenoscopes C and D or the automated endoscope reprocessors, *S maltophilia* and *Acinetobacter pittii* were cultured once from duodenoscope C. Contact patient screening did not detect *S maltophilia*, ESBL-producing *C freundii* or phenotypically identical *E cloacae* complex. In 7 of 81 patients (9%) an ESBL-producing *E coli* was found. However, comparing *E coli* isolates by molecular typing techniques proves to be difficult. Because the prevalence was similar to the current estimated population prevalence of 8%, the outbreak team decided not to further investigate possible *E coli* transmission. Because the detected A

**TABLE 1. Overview of the 27 MRKP case patients**

Patient no.	Scope	Age (y)/sex	Indication for ERCP	Intervention	L/S	Culture source	Culture indication
1	A	8/M	Benign biliary stricture (chronic pancreatitis)	PD stent removal and placement	S	Rectal swab	Screening
2	A	66/M	MBS (cholangiocarcinoma)	ES, dilation, biliary stent placement	L	Blood	Sepsis*
3	A	69/M	No ERCP: lower GI bleeding (CRC)	Endoscopic clip placement	L	Sputum, wound, blood, rectal swab	Sepsis*
4	A	67/M	MBS (pancreatic cancer)	ES, biliary stent placement	L	Rectal swab	Study sample
5†	A	74/M	Suspected pancreatitis by MBS (cholangiocarcinoma)	ES, dilation	L	Sputum, rectal swab	Abdominal infection‡
6	A+B	15/M	MBS (rhabdomyosarcoma)	ES, biliary stent placement	L	Feces, urine, throat	Abdominal infection‡
7	A	80/M	Suspected bile leak (metastatic CRC)	Dilation, biliary stent placement	S	Rectal swab	Screening
8	A+B	10/F	Biliary stricture of unknown cause	Brush, stent removal and placement	S	Rectal swab	Screening
9	A	63/M	Recurrent choledocholithiasis	Dilation, stone removal	S	Rectal swab	Screening
10	A	86/F	Choledocholithiasis	ES, biliary stone removal	L	Rectal swab	Study sample
11	A	67/F	MBS (cholangiocarcinoma)	Dilation, brush	L	Rectal swab	Study sample
12	A	73/M	PD leakage after partial pancreatic resection	ES, PD stent placement	S	Rectal swab	Screening
13	A	70/F	Choledocholithiasis	ES, dilation	L	Sputum	No symptoms
14	A	62/M	Chronic pancreatitis	PD stent placement	L	Blood	Sepsis*
15	A	72/F	MBS (suspected pancreatic cancer)	Biliary stent placement	L	Rectal swab	Study sample
16	A	48/F	MBS (pancreatic cancer)	ES, biliary stent placement	L	Rectal swab	Study sample
17	A+B	57/F	MBS (cholangiocarcinoma)	Dilation, biliary stent placement	L	Blood	Sepsis*
18	B	69/M	MBS (Suspected duodenal cancer)	No intervention	S	Rectal swab	Screening
19	A	53/F	Benign biliary stricture (chronic pancreatitis)	ES, biliary stent placement	L	Rectal swab	Study sample
20	B	70/M	Suspected bile leak after hemicolectomy (CRC)	ES	L	Rectal swab	Study sample
21	B	15/F	Suspected biliary stricture	ES	L	Bile	Cholangitis*
22	B	57/F	Suspected pancreatic cancer	ES, Biliary stent placement	S	Rectal swab	Screening
23	B	63/M	Suspected cholangiocarcinoma	ES, dilation	S	Rectal swab	Screening
24	A/B	58/F	MBS (pancreatic cancer)	Biliary stent placement	S	Rectal swab	Screening‡
25	B	40/M	Benign PD stricture (chronic pancreatitis)	PD cannulation	S	Rectal swab	Screening
26	A/B	62/M	Suspected cholangitis	Biliary stent placement	S	Rectal swab	Screening‡
27	B	72/M	MBS (metastatic CRC)	ES, dilation, biliary stent placement	L	Blood	Sepsis*

Infection: signs and symptoms of an active infection including at least fever ( $\geq 38.1^{\circ}\text{C}$ ) and other signs such as leukocytosis, sepsis, or septic shock. Study samples: rectal swabs were performed as part of another ongoing study conducted before the start of the outbreak investigation.

L/S, Laboratory database search/Screening of contact patients; A+B, patients underwent a procedure with duodenoscope A first and duodenoscope B later; A/B, patients underwent a procedure with duodenoscope A or B; CRC, colorectal cancer; ES, endoscopic sphincterotomy; MBS, malignant biliary stricture; MRKP, multidrug-resistant *K pneumoniae*; PD, pancreatic duct.

\*MRKP-related infection at presentation.

†Index patient.

‡MRKP-related sepsis at a later moment.

TABLE 2. Overview of cultured microorganisms from suspected duodenoscopes

Duodenoscope	Date (dd-mm-yyyy)	Sample site	Sample type	Microorganism	Quantity (colony-forming units)		
A TJF-Q180V	14-08-2015 After quarantining	Suction channel	Flush	MR-K <i>pneumoniae</i> *	>200		
				<i>S maltophilia</i>	>200		
				<i>P aeruginosa</i>	>200		
		Biopsy channel	Flush	MR-K <i>pneumoniae</i> *	>200		
				<i>K oxytoca</i>	>200		
				<i>S maltophilia</i>	>200		
				<i>P aeruginosa</i>	>200		
	Distal tip	Dryswab	Negative				
			19-08-2015 After second reprocessing	Suction channel	Flush	<i>C freundii</i>	1
				Biopsy channel	Flush	<i>S epidermidis</i>	12
	<i>S maltophilia</i>	22					
	<i>E cloacae</i> complex	1					
	Distal tip	Dryswab	CNS	1			
			19-08-2015 After second reprocessing	Flush	MR-K <i>pneumoniae</i> *	75	
<i>C freundii</i>					13		
<i>S maltophilia</i>	>200						
Distal tip	Pernasal Dryswab	Negative					
		Negative					
B TJF-Q180V	14-08-2015 After quarantining	Suction channel	Flush	MR-K <i>pneumoniae</i> *	28		
				<i>E coli</i>	3		
		Biopsy channel	Flush	<i>E faecium</i>	1		
				Distal tip	Dryswab	Negative	
	19-08-2015 After second reprocessing	Suction channel	Flush			MR-K <i>pneumoniae</i> *	6
				<i>E coli</i>	4		
				Biopsy channel	Flush	<i>E faecium</i>	1
		Distal tip	Dryswab			Negative	
						Distal tip	Pernasal Dryswab
		C TJF-160VR	21-08-2015	Suction channel	Flush		
Biopsy channel	Flush			<i>A pittii</i>	1		
Elevator channel	Flush			<i>A pittii</i>	26		
Brush					<i>S maltophilia</i>	6	
					<i>Corynebacterium</i> spp.	23	
					<i>Brevibacterium</i> spp.	6	
					<i>C jeikeium</i>	23	
					Negative		
25-08-2015 After second reprocessing	All cultures			Negative			
				Negative			
D TJF-160VR	21-08-2015	All cultures		Negative			

Duodenoscopes A and B were quarantined on August 13, 2015.

MR, Multidrug-resistant.

\*Isolates identical to the index isolates detected in clinical and screening cultures.

*pittii*, *P aeruginosa*, and *K oxytoca* isolates were susceptible for all tested antibiotics, the outbreak team decided further investigation was not indicated.

### Reprocessing audit

The reprocessing audit showed that the UMCU protocol (July 2013) had several deviations from the IFU 5.0 (May 2015). After review, the independent technical expert deemed 3 deviations as factors potentially influencing reprocessing efficacy.<sup>33</sup> First, the UMCU protocol did not explicitly state that the forceps elevator had to be moved in the upright and bent position during manual cleaning. Second, in June 2015, 5 months after the start of the outbreak, Olympus made the MAJ-1888 forceps elevator brush mandatory. The use of this brush had not yet been implemented; duodenoscopes were still brushed with the formerly mandatory BW-412T brush. Finally, leakage testing was not routinely performed under water but only if there was a suspicion of a leak.

### Dismantling of the duodenoscopes

The following results are a summary of the original extensive investigation report.<sup>33</sup> On December 15 and 16, 2015, duodenoscopes A and B were dismantled. No MRKP isolates were found in the 15 and 16 samples taken from duodenoscopes A and B, respectively. Two microorganisms of concern were cultured from the instrumentation port of duodenoscope B: 10 colony-forming units/100 mL *S maltophilia* and 10 colony-forming units/100 mL *E cloacae*. In both duodenoscopes damage and improper repairs were observed: brown staining behind the glass covering the light-guide lens (Fig. 2A); brown scale on the distal tip frame underneath the protective cap (Fig. 2B); actuator area cover plates incorrectly reattached with too little glue, sealing it incompletely (Fig. 2B); and new biopsy channels attached to the tip in a manner that deferred from the prescriptions of the duodenoscope manufacturer (Fig. 2C). In duodenoscope B, the following additional damage was observed: brown staining behind the objective lens of duodenoscope B (Fig. 2A); inadequate connection of the replaced protective cap, leaving space between the cap and the tip frame (Fig. 2D); loosened bonding of the cardan rubber, which covers the distal 10 cm of the endoscope before the distal tip (Fig. 2E); insufficient lubricant powder underneath the cardan rubber, likely having been the cause of friction damage to the outside of the distal end of the biopsy channel (Fig. 2F); and heavily oxidized electric circuits and connecting parts of the signaling tube in the control section, indicating moist damage (Fig. 2J). In duodenoscope A, a crack at the distal end on the inside of the biopsy channel was observed with the borescope (Fig. 2H).


Three design-related abnormalities were observed (Fig. 3). First, in both duodenoscopes brown staining was observed on the distal tips in places on the patient

side that were not reachable for brushes and poorly accessible for rinsing or drying: on the internal channel port side and on the patient-sided axis of the elevator lever (Fig. 3A), on the screw fastening the forceps elevator to the lever axis (Fig. 3B), in the groove in which the O-ring is situated (Fig. 3C), and in the axis hole of the forceps elevator (Fig. 3D). Second, at several places surrounding the forceps elevator that were easily accessible for brushes, white and brown oxidation stains were observed (Fig. 3E). Finally, water droplets were observed under the instrumentation port's rubber sealing ring of duodenoscope B (Fig. 3F).

### DISCUSSION

A rising number of reported outbreaks makes us question whether reprocessing of duodenoscopes is adequate enough to prevent infection of patients with exogenous microorganisms. In the outbreak described in this report, during 8 months, 2 duodenoscopes were persistently contaminated with identical MRKP isolates and infected  $\geq 29\%$  of all patients who underwent an ERCP procedure with 1 of the 2 duodenoscopes. In addition to standard outbreak investigations, this investigation included the full dismantling of both duodenoscopes and review of the audit and dismantling results by an independent expert. The investigations indicated a multifactorial etiology of the outbreak and showed that debris and thus possibly patient material were likely to have been transported onto sealed off areas. Four notable points of attention could have contributed to this: design issues hampering adequate cleaning, undetected damaged parts, construction defects after repairs, and flaws in the local reprocessing protocol. The results of this report invite critical evaluation of duodenoscope design, development of reliable maintenance and servicing, and transparent communication. These defensive layers will help to prevent further duodenoscope-associated infections.


High attack rates can lead to a large number of colonized and infected patients, especially if the outbreak continues unnoticed for many months. The 8 months' duration of this outbreak is no exception as other outbreaks are known to have been noticed after 4 or even up to 12 months.<sup>23-25,34-36</sup> During this outbreak, the duodenoscope attack rates of 35% and 29% resulted in 27 case patients. Other outbreak reports describe similar attack rates ranging from 12% to 41%<sup>23,35,37-39</sup> and patient counts of similar magnitude.<sup>1,23,24,34,36</sup> New Dutch and European surveillance strategies, developed in response to the outbreaks, potentially could shorten or even prevent outbreaks.<sup>40,41</sup> However, negative surveillance culture results do not exclude contamination: outbreaks continued under repeatedly negative surveillance cultures,<sup>36-38,42,43</sup> outbreak investigation cultures remained negative,<sup>34,39,44,45</sup>



**Figure 2.** Dismantling of duodenoscopes A and B, showing damage, oxidation, and incorrect repairs (photos adapted with permission).<sup>33</sup> The observations as shown in photos **A** and **C** were present in both duodenoscope A and B. **A**, Duodenoscope B. Close-up of the distal tip showing the light-guide lens and objective lens. Sludge was observed behind the glass that covers both lenses (arrows). **B**, Duodenoscope B. Close-up of the dismantled distal tip showing a brown layer on the frame of the distal tip and the cover plate of the actuator area that was incorrectly reused and reattached by soldering after repairs. **C**, Duodenoscope B. Close-up of the dismantled distal tip showing the incorrect fastening of the biopsy channel to the distal tip. **D**, Duodenoscope B. Close-up of the distal tip showing unwanted space between the tip frame and the protective cap (arrow). **E**, Duodenoscope B. Cardan rubber at the distal 10 cm of the duodenoscope and the distal tip. At the arrows loosening of the cardan rubber bonding was observed. **F**, Duodenoscope B. Outside of the distal part of the biopsy channel with damaged parts caused by friction (arrows). **G**, Borescope investigation. Both duodenoscopes had replaced biopsy channels with a ribbed structure instead of the original smooth structure. **H**, Duodenoscope A. Borescope showing a crack at the distal end of the biopsy channel near the tip (arrow). The biopsy channel was used for 20 procedures in total. **I**, Duodenoscope B. Borescope showing fibers at the distal end of the biopsy channel near the tip (arrows). **J**, Duodenoscope B. Control section: oxidation of electric circuits (left) and **K**, the connecting parts of the signaling tube (right).

or the microorganism was only cultured after dismantling of the duodenoscope.<sup>23,42</sup> Because the duodenoscope design hinders assessment of contamination, surveillance culturing might not be sensitive enough to prevent outbreaks.

In the TJF-Q180V duodenoscope design, areas of concern were observed that hamper adequate cleaning. These included the O-ring sealing that could potentially lead to leakage of moisture as described in 2012 by the same independent expert.<sup>26,27</sup> After the U.S. Food



**Figure 3.** Dismantling of duodenoscopes A and B, showing residue resulting from design issues (photos adapted with permission).<sup>33</sup> The observations as shown in photos **A** to **D** were present in both duodenoscope A and B. **A**, Duodenoscope A. Elevator lever with a brown layer on both sides of the O-ring: axis side (patient side) and the channel port side (sealed off by O-ring). **B**, Duodenoscope A. Scanning electron microscopy photographs of the screw that fastens the lever axis to the forceps elevator with a powdery, brown layer with organic characteristics in the screw thread. Detail scans, 255× (*left*) and 3600× (*right*). **C**, Duodenoscope A. Elevator lever and axis with the O-ring removed. A brown layer is seen in the groove of the O-ring. **D**, Duodenoscope A. Forceps elevator with brown layer around the axis hole. **E**, Duodenoscope A. White, porous-looking layer in the recess for the forceps elevator. **F**, **G**, Duodenoscope B. Instrumentation port: water droplets under the rubber ring that seals the port were observed.

and Drug Administration indicated that this modification of the earlier TJF-160VR design affected patient safety, Olympus revised the O-ring and started a recall of all TJF-Q180V worldwide in 2016.<sup>28</sup> Because the duodenoscopes involved in this outbreak had not been revised, this issue could have contributed to persistent contamination. In addition, brown deposits were observed around the lever axes, forceps elevators, and elevator screws of both duodenoscopes. Although located at the patient side of the distal tip, these places could not be reached with brushes and were poorly accessible for rinsing or drying. Scanning electron microscope images showed that the material looked similar to products of erosion or oxidation in presence of bacteria and appeared to have an organic character. However, the exact material composition could not be determined. Because these traces may have been remnants of moisture, it could not be ruled out that microorganisms had been present. Furthermore, in 1 duodenoscope water droplets were observed around the instrumentation port, which contained a nonoriginal O-

ring, despite the performance of the drying cycle exactly according to the IFU. This could point to either previous drying not in accordance with the IFU, improper repairs, or an inadequate IFU drying process. White and brown scale were observed at places around the forceps elevator that were well accessible for brushes. This could have been the result of inadequate brushing or an ineffective rinsing or drying process. Design issues that could hamper adequate decontamination should be critically evaluated.

Undetected damage may have contributed to several outbreaks because duodenoscopes without indications for servicing had critical abnormalities.<sup>12,25</sup> Dutch guidelines require annual technical endoscope inspections, which is performed by 75% of centers.<sup>46,47</sup> Institutional technicians could detect external damage (ie, concerning the cardan rubber, tip frame, or biopsy channel). Recently, Fujifilm, Pentax, and Olympus recommended annual inspections.<sup>28,48-50</sup> In this outbreak the biopsy channel must have been damaged in the short time of 3 months ahead of quarantining, when the duodenoscope was used for

only 20 procedures after the last replacement of the biopsy channel. This is in line with recent borescope studies stating that biopsy channels of all types of endoscopes are frequently damaged,<sup>31</sup> even as early as after 4 weeks of use,<sup>29</sup> which may add to the risk of contamination.<sup>51</sup> The American Society for Gastrointestinal Endoscopy warns that endoscope durability is understood incompletely.<sup>52</sup> Assessment of the critical number of procedures after which to perform inspection or preventive maintenance might help to understand the development of endoscope wear and reduce the chance of using critically damaged endoscopes.

Institutions should be able to rely on repaired duodenoscopes being of similar quality as a new one, regardless if repairs are performed by the manufacturer or by ISOs. This investigation showed several inadequately conducted repairs, including incorrectly attached arm covers and biopsy channels of both duodenoscopes. In some cases, parts were reused or replaced with materials not originating from Olympus. In addition to aforementioned O-ring design issues, nearly all inadequate repairs could have contributed to the persistence of microorganisms. However, the investigation could not reconstruct the exact route of contamination. In 70% of Dutch centers, institutional technicians perform by Dutch guidelines required inspections of repaired endoscopes, often finding functional irregularities concerning the flexibility of the tip and the position of the spray nozzle.<sup>46,47</sup> However, institutional technicians may lack expertise or instruments such as borescopes for adequate assessment, and some inadequate repairs can only be revealed after dismantling. Although servicing of medical devices by ISOs is essential to the U.S. healthcare system,<sup>53</sup> the U.S. Food and Drug Administration and American Society for Gastrointestinal Endoscopy acknowledged concerns about the quality of servicing.<sup>53,54</sup> ISOs may experience difficulties in obtaining servicing manuals, technical specifications, training, and replacement parts from original manufacturers.<sup>53,54</sup> In the Netherlands, Olympus does not sell spare parts for the TJF-Q180V duodenoscopes; as a result, ISOs choose to use nonoriginal materials. Perhaps the repair quality could be improved if ISOs would service devices in agreement with manufacturers, the latter providing access to necessary materials and information.<sup>54</sup> Also, communication between all involved parties can be improved.<sup>1</sup> For example, U.S. manufacturers and institutions are not obligated to notify ISOs about adverse events related to servicing of the device.<sup>53</sup> A more transparent market would support reliable and affordable high-quality servicing.

In addition to duodenoscope-related risks, reprocessing itself is error-prone.<sup>20-22</sup> In multiple outbreaks reprocessing breaches may have contributed.<sup>35-37,42,55</sup> In response to the finding that the TJF-Q180V design hampered adequate cleaning, Olympus issued a Safety Advice in 2013.<sup>23,56</sup> The advice indicated, among other warnings,

detailed forceps elevator brushing instructions to reach all crevices. Although not explicitly stated in the UMCU protocol, during the audit these actions were performed by disinfection assistants.<sup>33</sup> Olympus also suggested the use of the new designated MAJ-1888 brush. This was made mandatory in June 2015, 5 months after this outbreak started. Because the UMCU leakage testing was not performed underwater unless a leak was suspected, leaks may have been missed. The repair history of duodenoscope B listed the assessment of a potential leak, which may explain the oxidation around the electrical connection in the control section. During the external review both the IFU leakage test and the Olympus automated endoscope reprocessor automatic leakage test did not detect any aberrations. Recently, the European guideline questioned if leakage testing was accurate enough because micro-defects were often not detected.<sup>40</sup> To ensure direct implementation of recommendations, the independent expert advised manufacturers to communicate new reprocessing clearly and to make critical recommendations mandatory right away.<sup>35</sup> Hospitals should, in addition to direct implementation, also perform recurring audits. This was essential in our center to minimize protocol breaches after the outbreak investigation.

This is the second report that describes the dismantling of duodenoscopes in an outbreak setting.<sup>23</sup> Both hospitals and manufacturers were open to critical review by an experienced independent expert, enabling the investigation of all potential causes for contamination. The procedure described in this report has limitations. Dismantling took place 4 months after quarantining, which may have contributed to culture results negative for MRKP in any of the dismantled parts. Therefore, the exact location of the persistent contaminant could not be traced. Furthermore, the reprocessing audit took place after the outbreak. This may have influenced the responses of the disinfection assistants. Finally, not all findings may apply to other centers. Duodenoscope contamination incidences differ between hospitals,<sup>11</sup> possibly because of differing control rigidity, surveillance, and maintenance strategies.

This report describes how a combination of factors including duodenoscope design issues, undetected damaged parts, inadequate repairs, nontransparent communication, and inadequate hospital protocols may have contributed to the outbreak. The reliability of the defensive layers of the current system around reusable duodenoscopes seems to show room for improvement because of several factors: reprocessing with small margins of safety while human errors are to be expected,<sup>16-22</sup> imperfect maintenance strategies, duodenoscope designs that can hamper adequate cleaning,<sup>23,57</sup> unclear communication, and imperfect adverse event reporting.<sup>1,8</sup> To develop better defensive layers and avoid unreported internal assessment by the manufacturer,<sup>25,57</sup> we suggest independent reviews of future outbreaks including a timely full dismantling of the duodenoscope. Furthermore,

adapted duodenoscope designs may currently be marketed without additional clinical testing, if sufficiently based on previously approved designs. Peer-reviewed validation tests are only obligatory for radically altered designs, which are assessed by manufacturers themselves. However, because successive adjustments can result in a substantial different design, standard peer-reviewed design validation tests could contribute to safer duodenoscope designs. In the short term, the number of duodenoscope-associated outbreaks could be reduced by direct implementation of critical reprocessing measures, a reliable servicing market, critical review of current monitoring methods, and introduction of surveillance measures. Eventually, new duodenoscope designs and reprocessing procedures with a larger margin of safety are required.

## ACKNOWLEDGMENTS

We thank the reprocessing staff, medical devices experts, infection control practitioners, medical microbiologists, Bio Information Technology group, and gastroenterologists at the UMCU for their participation and effort in this outbreak investigation. The authors received no specific funding support for the research, authorship, and/or publication of this article.

## REFERENCES

1. U.S. Senate. Preventable tragedies: superbugs and how ineffective monitoring of medical device safety fails patients. 2016. [updated 13-01-2016]. Available at: <https://www.help.senate.gov/imo/media/doc/Duodenoscope%20Investigation%20FINAL%20Report.pdf>. Accessed January 21, 2016.
2. Rubin ZA, Kim S, Thaker AM, et al. Safely reprocessing duodenoscopes: current evidence and future directions. *Lancet Gastroenterol Hepatol* 2018;3:499-508.
3. Petersen BT, Koch J, Ginsberg GG. Infection using ERCP endoscopes. *Gastroenterology* 2016;151:46-50.
4. Kovaleva J, Peters FT, van der Mei HC, et al. Transmission of infection by flexible gastrointestinal endoscopy and bronchoscopy. *Clin Microbiol Rev* 2013;26:231-54.
5. ASGE Standards of Practice Committee; Chandrasekhara V, Khashab MA, Muthusamy VR, et al. Adverse events associated with ERCP. *Gastrointest Endosc* 2017;85:32-47.
6. Lin JN, Wang CB, Yang CH, et al. Risk of infection following colonoscopy and sigmoidoscopy in symptomatic patients. *Endoscopy* 2017;49:754-64.
7. Wang P, Xu T, Ngamruengphong S, et al. Rates of infection after colonoscopy and oesophagogastroduodenoscopy in ambulatory surgery centres in the USA. *Gut* 2018;67:1626-36.
8. U.S. Food and Drug Administration. Statement from Jeff Shuren, M.D., J.D., Director of the Center for Devices and Radiological Health, on updated safety communication about rates of duodenoscope contamination from preliminary postmarket data 2018 [updated 10-12-2018]. Available at: <https://www.fda.gov/NewsEvents/Newsroom/PressAnnouncements/ucm628096.htm>. Accessed December 10, 2018.
9. Decristoforo P, Kaltseis J, Fritz A, et al. High-quality endoscope reprocessing decreases endoscope contamination. *Clin Microbiol Infect* 2018;24:1101.
10. Snyder GM, Wright SB, Smithey A, et al. Randomized comparison of 3 high-level disinfection and sterilization procedures for duodenoscopes. *Gastroenterology* 2017;153:1018-25.
11. Brandabur JJ, Leggett JE, Wang L, et al. Surveillance of guideline practices for duodenoscope and linear echoendoscope reprocessing in a large healthcare system. *Gastrointest Endosc* 2016;84:392-9.
12. Ross AS, Baliga C, Verma P, et al. A quarantine process for the resolution of duodenoscope-associated transmission of multidrug-resistant *Escherichia coli*. *Gastrointest Endosc* 2015;82:477-83.
13. Alfa MJ, Olson N, DeGagne P, et al. A survey of reprocessing methods, residual viable bioburden, and soil levels in patient-ready endoscopic retrograde cholangiopancreatography duodenoscopes used in Canadian centers. *Infect Control Hosp Epidemiol* 2002;23:198-206.
14. Saliou P, Le Bars H, Payan C, et al. Measures to improve microbial quality surveillance of gastrointestinal endoscopes. *Endoscopy* 2016;48:704-10.
15. Rauwers AW, Voor In't Holt AF, Buijs JG, et al. High prevalence rate of digestive tract bacteria in duodenoscopes: a nationwide study. *Gut* 2018;67:1637-45.
16. Rutala WA, Weber DJ. Outbreaks of carbapenem-resistant Enterobacteriaceae infections associated with duodenoscopes: What can we do to prevent infections? *Am J Infect Control* 2016;44:e47-51.
17. Roberts CG. Studies on the bioburden on medical devices and the importance of cleaning. In: Rutala WA (ed) *Disinfection, sterilization and antisepsis: principles and practices in healthcare facilities*. Washington, DC: Association for Professional in Infection Control and Epidemiology; 2001. p. 63-9.
18. Alfa MJ, Degagne P, Olson N. Worst-case soiling levels for patient-used flexible endoscopes before and after cleaning. *Am J Infect Control* 1999;27:392-401.
19. Rutala WA, Weber DJ. FDA labeling requirements for disinfection of endoscopes: a counterpoint. *Infect Control Hosp Epidemiol* 1995;16:231-5.
20. Ofstead CL, Wetzler HP, Snyder AK, et al. Endoscope reprocessing methods: a prospective study on the impact of human factors and automation. *Gastroenterol Nurs* 2010;33:304-11.
21. Dirlam Langlay AM, Ofstead CL, Mueller NJ, et al. Reported gastrointestinal endoscope reprocessing lapses: the tip of the iceberg. *Am J Infect Control* 2013;41:1188-94.
22. Schaefer MK, Jhung M, Dahl M, et al. Infection control assessment of ambulatory surgical centers. *JAMA* 2010;303:2273-9.
23. Verfaillie CJ, Bruno MJ, Voor in't Holt AF, et al. Withdrawal of a novel-design duodenoscope ends outbreak of a VIM-2-producing *Pseudomonas aeruginosa*. *Endoscopy* 2015;47:493-502.
24. Epstein L, Hunter JC, Arwady MA, et al. New Delhi metallo-beta-lactamase-producing carbapenem-resistant *Escherichia coli* associated with exposure to duodenoscopes. *JAMA* 2014;312:1447-55.
25. Wendorf KA, Kay M, Baliga C, et al. Endoscopic retrograde cholangiopancreatography-associated AmpC *Escherichia coli* outbreak. *Infect Control Hosp Epidemiol* 2015;36:634-42.
26. Loeve AJ. Investigational report on a TJF-Q180V duodenoscope following contamination after cleaning and disinfection. Available on request from the Dutch Healthcare Inspectorate/National Institute for Public Health and the Environment. Bilthoven. The Netherlands; 2012. Accessed October 1, 2015.
27. Bruijn ACPd, Drongelen AWv. Desinfection of the Olympus TJF-Q180V ERCP endoscope. RIVM Adviespunt Medische en Consumentenproducten. Projectnummer: V/080118/01/AH. Bilthoven, the Netherlands: National Institute for Public Health and the Environment/Rijksinstituut voor Volksgezondheid en Milieu RIVM; 2012.
28. U.S. Food and Drug Administration. FDA clears Olympus TJF-Q180V duodenoscope with design modifications intended to reduce infection risk. 2016. [updated 15-01-2016]. Available at: [www.fda.gov/NewsEvents/Newsroom/PressAnnouncements/ucm481956.htm](http://www.fda.gov/NewsEvents/Newsroom/PressAnnouncements/ucm481956.htm). Accessed January 21, 2016.
29. Thaker AM, Kim S, Sedarat A, et al. Inspection of endoscope instrument channels after reprocessing using a prototype borescope. *Gastrointest Endosc* 2018;88:612-9.

30. Ofstead CL, Wetzler HP, Heymann OL, et al. Longitudinal assessment of reprocessing effectiveness for colonoscopes and gastroscopes: results of visual inspections, biochemical markers, and microbial cultures. *Am J Infect Control* 2017;45:e26-33.
31. Visrodia K, Petersen BT. Borescope examination: Is there value in visual assessment of endoscope channels? *Gastrointest Endosc* 2018;88:620-3.
32. Advisory Board Cleaning and Disinfection Flexible Endoscopes (SFERD). Professional standard handbook, version 3.0. Flexible endoscope—cleaning and disinfection. 2013. [updated 18-09-2013]. Available at: [https://www.infectiepreventieopleidingen.nl/downloads/SFERDHandbook3\\_1.pdf](https://www.infectiepreventieopleidingen.nl/downloads/SFERDHandbook3_1.pdf). Accessed October 1, 2016.
33. Loeve AJ. Investigation of Olympus TJF-Q180V scopes at UMC Utrecht regarding contamination found after cleaning and disinfection: reporting, conclusions and suggestions 2017. Available at: <http://resolver.tudelft.nl/uuid:e8d991bd-7463-4a7b-b574-86efbd42db62>. Accessed: January 5, 2017.
34. Kim S, Russell D, Mohamadnejad M, et al. Risk factors associated with the transmission of carbapenem-resistant Enterobacteriaceae via contaminated duodenoscopes. *Gastrointest Endosc* 2016;83:1121-9.
35. Alrabaa SF, Nguyen P, Sanderson R, et al. Early identification and control of carbapenemase-producing *Klebsiella pneumoniae*, originating from contaminated endoscopic equipment. *Am J Infect Control* 2013;41:562-4.
36. Aumeran C, Poincloux L, Souweine B, et al. Multidrug-resistant *Klebsiella pneumoniae* outbreak after endoscopic retrograde cholangiopancreatography. *Endoscopy* 2010;42:895-9.
37. Carbonne A, Thiolet JM, Fournier S, et al. Control of a multi-hospital outbreak of KPC-producing *Klebsiella pneumoniae* type 2 in France, September to October 2009. *Eur Surveill* 2010;15:19734.
38. Valderrama S, Miranda CJL, Rubio ÁPG, et al. successful control of an endoscopic retrograde cholangiopancreatography-associated nosocomial outbreak caused by *Klebsiella pneumoniae* carbapenemase producing *Klebsiella pneumoniae* in a university hospital in Bogota, Colombia. *Open Forum Infect Dis* 2016;3:1398.
39. Kola A, Piening B, Pape UF, et al. An outbreak of carbapenem-resistant OXA-48-producing *Klebsiella pneumoniae* associated to duodenoscopy. *Antimicrob Resist Infect Control* 2015;4:8.
40. Beilenhoff U, Biering H, Blum R, et al. Prevention of multidrug-resistant infections from contaminated duodenoscopes: position statement of the European Society of Gastrointestinal Endoscopy (ESGE) and European Society of Gastroenterology Nurses and Associates (ESGENA). *Endoscopy* 2017;49:1098-106.
41. Dutch Association for Medical Microbiology (NVMM). Guideline: control of microbiological safety of thermolabile flexible high-risk gastrointestinal endoscopes [Richtlijn controle op microbiologische veiligheid van thermolabele flexibele hoog-risico gastro-intestinale endoscopen]. 2018. Available at: <https://www.nvmm.nl/media/2222/180627-richtlijn-controle-op-microbiologische-veiligheid-van-thermolabele-flexibele-gi-endoscopen-juiste-versie.pdf>. Accessed April 1, 2018.
42. Kovaleva J, Meessen NE, Peters FT, et al. Is bacteriologic surveillance in endoscope reprocessing stringent enough? *Endoscopy* 2009;41:913-6.
43. Fraser TG, Reiner S, Malczynski M, et al. Multidrug-resistant *Pseudomonas aeruginosa* cholangitis after endoscopic retrograde cholangiopancreatography: failure of routine endoscope cultures to prevent an outbreak. *Infect Control Hosp Epidemiol* 2004;25:856-9.
44. Smith ZL, Oh YS, Saeian K, et al. Transmission of carbapenem-resistant Enterobacteriaceae during ERCP: time to revisit the current reprocessing guidelines. *Gastrointest Endosc* 2015;81:1041-5.
45. Bourigault C, Le Gallou F, Bodet N, et al. Duodenoscopy: an amplifier of cross-transmission during a carbapenemase-producing Enterobacteriaceae outbreak in a gastroenterology pathway. *J Hosp Infect* 2018;99:422-6.
46. Advisory Board Cleaning and Disinfection Flexible Endoscopes (SFERD). Professional standard handbook, version 4.0. Flexible endoscopes—cleaning and disinfection. 2016. [updated 01-09-2016]. Available at: [https://www.infectiepreventieopleidingen.nl/downloads/SFERDHandbook4\\_1.pdf](https://www.infectiepreventieopleidingen.nl/downloads/SFERDHandbook4_1.pdf). Accessed October 1, 2016.
47. Bruijn ACPd, Drongelen AWv. Control measures for the use of endoscope disinfectors: progress of the implementation of the SFERD quality manual. 2018. Available at: <http://hdl.handle.net/10029/622063>. Accessed: November 7, 2018.
48. Olympus Medical System Corp. Customer letter: Urgent medical device removal and corrective action. Elevator mechanism replacement, updated operation manual, and new reprocessing instructions for the Olympus TJF-Q180V duodenoscope 2016 [updated 15-01-2016]. Available at: <http://medical.olympusamerica.com/sites/us/files/pdf/160115-Olympus-TJF-Q180V-Customer-Letter.pdf>. Accessed January 21, 2016.
49. Fujifilm Medical System U.S.A. Urgent medical device correction and removal. 2017. [updated 21-07-2017]. Available at: [https://www.fujifilmusa.com/products/medical/endoscopy/pdf/UrgentFieldCorrectionAndRemoval\\_ED530XT\\_072117.pdf](https://www.fujifilmusa.com/products/medical/endoscopy/pdf/UrgentFieldCorrectionAndRemoval_ED530XT_072117.pdf). Accessed February 11, 2018.
50. Pentax of America Inc. ED34-i10T traditional 510(k) submission 2017. [updated 18-09-2017]. Available at: [https://www.accessdata.fda.gov/cdrh\\_docs/pdf16/K163614.pdf](https://www.accessdata.fda.gov/cdrh_docs/pdf16/K163614.pdf). Accessed February 11, 2018.
51. Lee DH, Kim DB, Kim HY, et al. Increasing potential risks of contamination from repetitive use of endoscope. *Am J Infect Control* 2015;43:e13-7.
52. Reprocessing Guideline Task Force; Petersen BT, Cohen J, Hambrick III RD, et al. Multisociety guideline on reprocessing flexible GI endoscopes: 2016 update. *Gastrointest Endosc* 2017;85:282-94.
53. U.S. Food and Drug Administration. FDA report on the quality, safety, and effectiveness of servicing of medical devices. In accordance with Section 710 of the Food and Drug Administration Reauthorization Act of 2017 (FDARA) 2018 [updated 01-05-2018]. Available at: <https://www.fda.gov/media/113431/download>. Accessed August 3, 2018.
54. Ginsberg GG, Barkun AN, Bosco JJ, et al. Endoscope repair by original equipment manufacturers and independent service organizations. *Gastrointest Endosc* 2003;57:639-42.
55. Robertson P, Smith A, Anderson M, et al. Transmission of *Salmonella enteritidis* after endoscopic retrograde cholangiopancreatography because of inadequate endoscope decontamination. *Am J Infect Control* 2017;45:440-2.
56. Olympus Medical System Corp. Important safety advice. Safe reprocessing of TJF-Q180V. 2013. Available at: <http://www.mcelandrewyoung.com/wp-content/uploads/2015/04/olympuseuropajan2013letter.pdf>. Accessed January 10, 2015.
57. Shenoy ES, Pierce VM, Walters MS, et al. Transmission of mobile colistin resistance (mcr-1) by duodenoscope. *Clin Infect Dis* 2018;68:1327-34.