

Alzheimer's Imaging Consortium

Georgiadis, Marios; Auf der Heiden, Franca; Nirschl, Jeffrey; Liu, Andy; Taghavi, Hossein Moein; Amunts, Katrin; Axer, Markus; Menzel, Miriam; Zeineh, Michael

DOI

[10.1002/alz70862_110123](https://doi.org/10.1002/alz70862_110123)

Licence

CC BY

Publication date

2025

Document Version

Final published version

Published in

Alzheimer's & dementia : the journal of the Alzheimer's Association

Citation (APA)

Georgiadis, M., Auf der Heiden, F., Nirschl, J., Liu, A., Taghavi, H. M., Amunts, K., Axer, M., Menzel, M., & Zeineh, M. (2025). Alzheimer's Imaging Consortium. *Alzheimer's & dementia : the journal of the Alzheimer's Association*, 21(S8), Article e110123. https://doi.org/10.1002/alz70862_110123

Important note

To cite this publication, please use the final published version (if applicable).
Please check the document version above.

Copyright

Other than for strictly personal use, it is not permitted to download, forward or distribute the text or part of it, without the consent of the author(s) and/or copyright holder(s), unless the work is under an open content license such as Creative Commons.

Takedown policy

Please contact us and provide details if you believe this document breaches copyrights.
We will remove access to the work immediately and investigate your claim.

HUMAN NEUROPATHOLOGY

Mapping neuronal trajectories in neurodegeneration independent of sample preparation

Marios Georgiadis¹ | Franca auf der Heiden² | Jeffrey Nirschl¹ | Andy Liu¹ | Hossein Moein Taghavi¹ | Katrin Amunts³ | Markus Axer² | Miriam Menzel⁴ | Michael Zeineh¹

¹Stanford University, Stanford, CA, USA

²Forschungszentrum Jülich, Jülich, Germany

³Institute of Neuroscience and Medicine (INM-1), Jülich, Germany

⁴Delft University of Technology, Delft, Netherlands

Correspondence

Marios Georgiadis, Stanford University, Stanford, CA, USA.

Email: mariosg@stanford.edu

Abstract

Background: The brain's nerve fiber network is disturbed in neurodegeneration, but resolving fiber trajectories over large fields-of-view to study connectivity changes remains prohibitive. Current methods study small volumes (electron microscopy), have limited resolution (diffusion MRI), or need birefringence-preserving sample preparation and cannot resolve crossings (polarization microscopy). Here we show that computational scattered light imaging (ComSLI) resolves neuronal trajectories, including degenerating hippocampal tracts, with micron resolution in any histology section independent of sample preparation.

Methods: We studied standard-sized 5-10 μ m formalin-fixed paraffin-embedded (FFPE) sections prepared using various protocols (cf. text/figures) and two whole-brain sections (Figure 1 – FFPE, from the Jülich BigBrain, 20 μ m, silver-stained, and Figure 2E - celloidin-embedded and myelin-stained in 1904, from the Institute for Brain Research, Düsseldorf, Germany).

Computational scattered light imaging (ComSLI) was performed in Stanford and Jülich. The setup (Figure 1A,B) includes a micron-resolution low angle-of-acceptance camera-adaptor-lens system and a rotating LED lightsource. Images were acquired at 5-15° rotation steps (24-72 images/sample), with 3-9 μ m pixel size. Motorized stages enable tile-scanning. SLIX software quantified orientations, MATLAB was used for orientation analysis, and MRtrix3 for creating orientation distribution functions and subsequent tractography.

Result: ComSLI produced a micron-resolution whole-brain fiber orientation map (Figure 1C). Figures 1D-E show zoomed-in fiber orientations in corpus callosum/fornix and corona radiata. Microscopic resolutions enabled generating fiber orientation distributions at multiple scales (Figure 1F), leading to microstructure-informed whole-brain tracts (Figure 1G-H).

This is an open access article under the terms of the [Creative Commons Attribution](https://creativecommons.org/licenses/by/4.0/) License, which permits use, distribution and reproduction in any medium, provided the original work is properly cited.

© 2025 The Alzheimer's Association. *Alzheimer's & Dementia* published by Wiley Periodicals LLC on behalf of Alzheimer's Association.

ComSLI works for various sample preparation protocols (Figure 2). Consecutive human hippocampal sections with different stains (iron, microglia, tau, and amyloid) show identical orientations (Figure 2B,C), quantified after co-registration in Figure 2D. Orientations were also derived from a 120-year-old human section (Figure 2E-F), and were consistent at various sample preparation steps (Figure 2G).

ComSLI can study neurodegenerating tracts, such as the hippocampal perforant pathway (Figure 3). A healthy hippocampus includes strong perforant pathway connections through the subiculum and CA1 subfields (Figure 3A-F), which almost entirely disappear in a sclerotic hippocampus (Figure 3G-L), and are severely compromised in Alzheimer's disease (Figure 3M-R).

Conclusion: ComSLI is a cost-effective method to study intricate fiber networks at micron-resolution in any histological tissue section, and can reveal subtle changes in neurodegeneration.

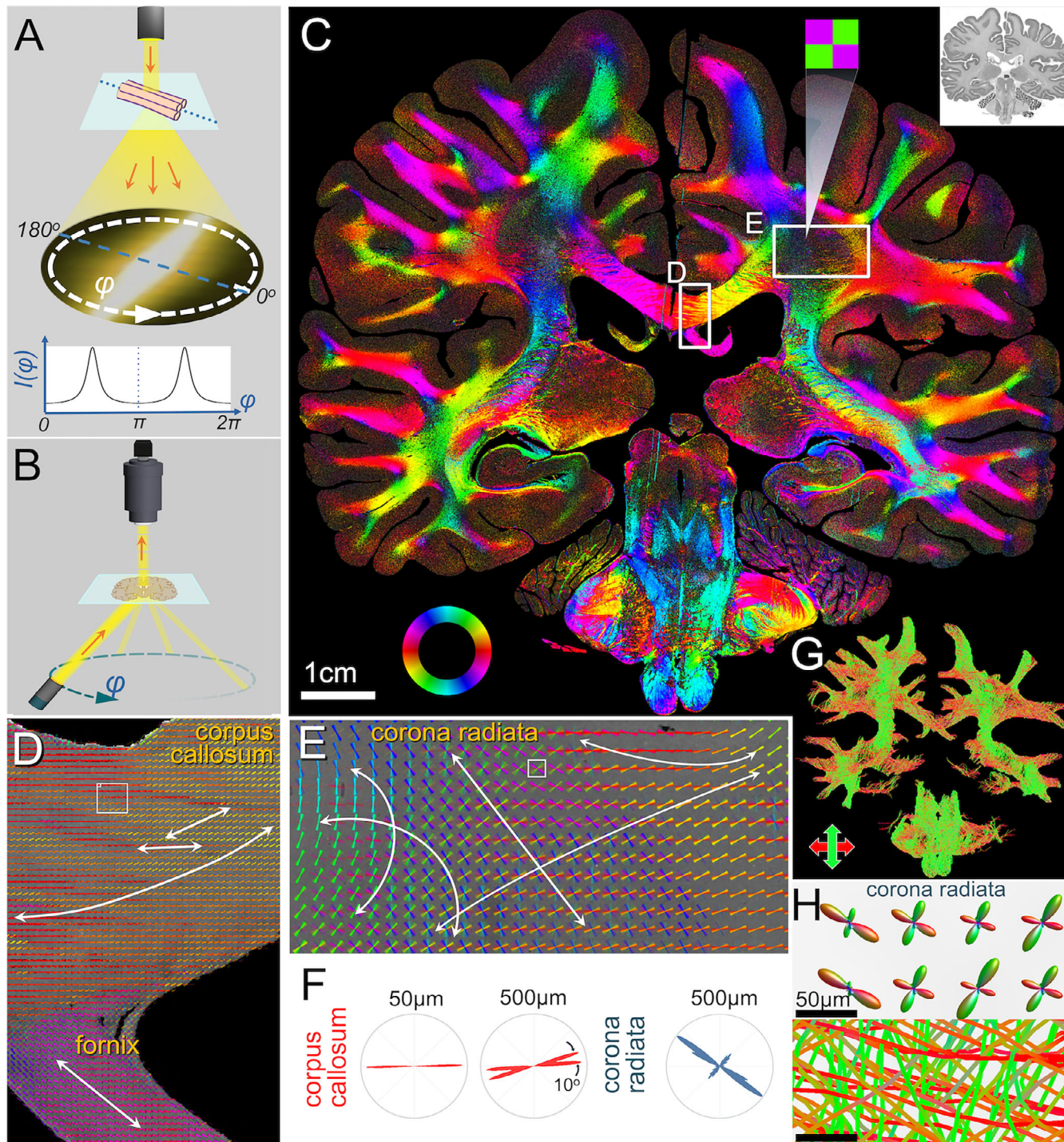


Figure 1. **A)** ComSLI principle. Light scatters mostly perpendicularly off oriented fibers creating a peak pair in the azimuthal light intensity profile. **B)** ComSLI setup. A rotating lightsource illuminates the sample while a camera captures micron-resolution images at each angle ϕ . **C)** Fiber orientation map of the BigBrain section (inset), $7\mu\text{m}/\text{pixel}$. The fiber orientations are encoded according to the color wheel in the bottom left; multiple colors per pixel indicate multiple fiber orientations, e.g., in the corona radiata. **D-E)** Fiber orientations for boxes marked in C, encoded both by the line direction and its color. **F)** Microscopic orientation distributions corresponding to the squares in D-E. **G)** Whole-brain tractogram. **H)** Corona radiata detail of microscopic fiber orientation distribution functions and tracts crossing the same pixels (at the location of the square in E).

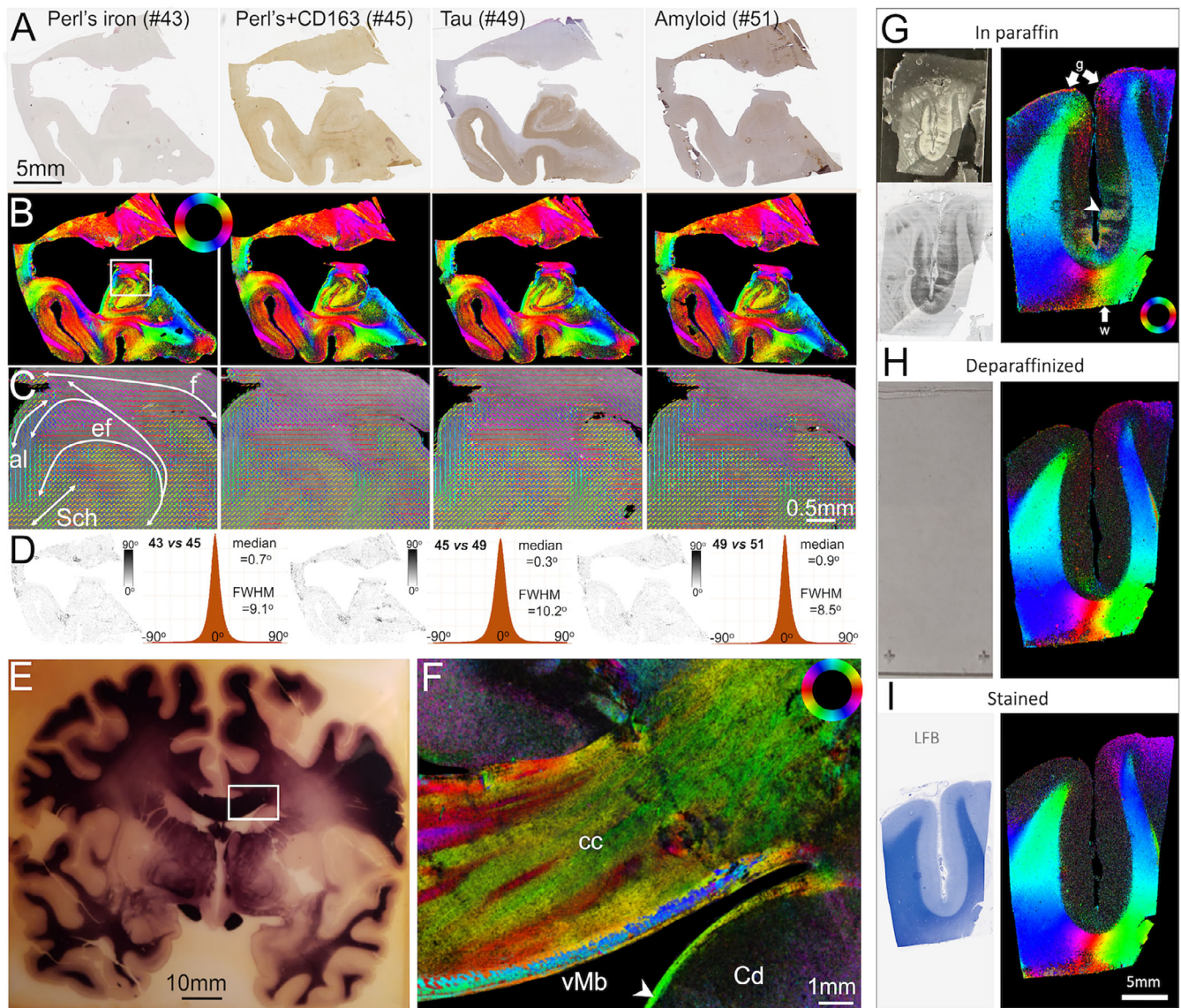


Figure 2. ComSLI detects fiber orientations independent of tissue preparation. **A-C**) Human hippocampi, FFPE sections with different stains. **A**) Brightfield microscopy images, 0.5 μ m/pixel. **B**) ComSLI fiber orientation maps, 7 μ m/pixel, orientations encoded by color wheel. **C**) Zoomed-in fiber orientation vector maps (white box in (B)), including parts of cornu ammonis and multiple tracts: fornix (f), endfolial pathway (ef), alveus (al), Schaffer collaterals (Sch). Vectors of 15x15 pixels are overlaid. **D**) Orientation difference for each pair of consecutive sections, as map (left) and histogram (right), with medial value and full-width-half-maximum (FWHM) reported. **E-F**) Myelin-stained human brain section (~120-year-old). **E**) Section photograph. **F**) ComSLI color-coded fiber orientation map (3 μ m/pixel) of marked region in (E), cc: corpus callosum, Cd: Caudate nucleus, Mb: Muratoff bundle (arrowhead). **G-I**) ComSLI at different steps of FFPE sample preparation. **G**) Section still in paraffin, with white (w) and gray (g) matter fiber orientations, despite evident paraffin structures in the photo (top left) and slide-scanned image below. **H**) The same section after deparaffinization, before staining. The section lacks brightfield contrast for slide-scanning so only photo is shown. **I**) The same sections after luxol fast blue (LFB) staining, where orientations follow the same orientation patterns. Sections still in paraffin (G) have stronger gray matter orientations, but are also prone to small artifacts, e.g., from folding (arrow in middle of section).




Figure 3. ComSLI sensitively detects degenerative changes in hippocampal tracts. **A-F** Hippocampus of healthy aged subject. **G-L** Hippocampus of subject with epileptic hippocampal sclerosis. **M-R** Hippocampus of subject with Alzheimer's Disease. **Top row:** (A,G,M) Brightfield microscopy images of H&E (A,G) and tau (M) stains, 0.5µm/pixel. (B,H,N) ComSLI average scattering map, 7µm/pixel, with hippocampal subfields identified (SUB: subiculum, DG: dentate gyrus, CA1/3: cornu ammonis 1/3, ERC: entorhinal cortex). **Second row:** (C,I,O) Fiber orientation maps, 7µm/pixel, orientations encoded by color wheel. Perforant pathway (p) direction highlighted by arrows. **Third row:** (D,J,P) Zoomed-in fiber orientation vector maps of white boxes in (C,I,O), including the perforant pathway crossing the subiculum and/or CA1. Vectors of 15x15 pixels are overlaid. **Fourth row:** (E,K,Q) Orientation distribution functions (ODFs) representing fibers orientations at 50µm resolution, with perforant tract directions highlighted. **Bottom row (F,L,R):** Tractograms derived from the ODFs. The control perforant pathway (F) has strong connections (black arrows), whereas the perforant pathway tracts in the sclerotic hippocampus (L) are very scarce, while they are significantly reduced in the Alzheimer's Disease hippocampus.