

Document Version

Final published version

Licence

CC BY

Citation (APA)

van Buuren, M. M. A., Arden, N. K., Bierma-Zeinstra, S. M. A., Bramer, W. M., Casartelli, N. C., Felson, D. T., Jones, G., Lane, N. E., Lindner, C., Weinans, H., & More Authors (2021). Statistical shape modeling of the hip and the association with hip osteoarthritis: a systematic review. *Osteoarthritis and Cartilage*, 29(5), 607-618.
<https://doi.org/10.1016/j.joca.2020.12.003>

Important note

To cite this publication, please use the final published version (if applicable).
Please check the document version above.

Copyright

In case the licence states "Dutch Copyright Act (Article 25fa)", this publication was made available Green Open Access via the TU Delft Institutional Repository pursuant to Dutch Copyright Act (Article 25fa, the Taverne amendment). This provision does not affect copyright ownership.
Unless copyright is transferred by contract or statute, it remains with the copyright holder.

Sharing and reuse

Other than for strictly personal use, it is not permitted to download, forward or distribute the text or part of it, without the consent of the author(s) and/or copyright holder(s), unless the work is under an open content license such as Creative Commons.

Takedown policy

Please contact us and provide details if you believe this document breaches copyrights.
We will remove access to the work immediately and investigate your claim.

Osteoarthritis and Cartilage

Review

Statistical shape modeling of the hip and the association with hip osteoarthritis: a systematic review



M.M.A. van Buuren †*, N.K. Arden ‡§, S.M.A. Bierma-Zeinstra †||, W.M. Bramer ¶, N.C. Casartelli # ††, D.T. Felson ††§§ ||||, G. Jones ¶¶, N.E. Lane ##, C. Lindner †††, N.A. Maffiuletti #, J.B.J. van Meurs †††, A.E. Nelson §§§, M.C. Nevitt |||||, P.L. Valenzuela ¶¶¶, J.A.N. Verhaar †, H. Weinans ### ††††, R. Agricola †

† Department of Orthopedics, Erasmus MC, University Medical Center Rotterdam, Rotterdam, the Netherlands

‡ Nuffield Department of Orthopedics, Rheumatology and Musculoskeletal Sciences, University of Oxford, Oxford, UK

§ NIHR Musculoskeletal Biomedical Research Unit, Arthritis Research UK Centre for Sport, Exercise, and Osteoarthritis, University of Oxford, Oxford, UK

|| Department of General Practice and Department of Orthopedics, Erasmus MC, University Medical Center Rotterdam, Rotterdam, the Netherlands

¶ Medical Library, Erasmus MC, University Medical Center Rotterdam, Rotterdam, the Netherlands

Human Performance Lab, Schulthess Clinic, Zürich, Switzerland

†† Laboratory of Exercise and Health, ETH Zürich, Schwerzenbach, Switzerland

††† Centre for Epidemiology Versus Arthritis, Faculty of Biology, Medicine and Health, Manchester Academic Health Science Centre, The University of Manchester, Manchester, UK

§§§ NIHR Manchester Biomedical Research Centre, Manchester University NHS Foundation Trust, Manchester Academic Health Science Centre, Manchester, UK

|||| Department of Rheumatology, Boston University School of Medicine, Boston, MA, USA

¶¶ Menzies Institute for Medical Research, University of Tasmania, Hobart, Tasmania, Australia

Department of Medicine, University of California, Davis, CA, USA

††† Division of Informatics, Imaging & Data Sciences, University of Manchester, Manchester, UK

†††† Department of Internal Medicine, Erasmus MC, University Medical Center Rotterdam, Rotterdam, the Netherlands

§§§§ Thurston Arthritis Research Center and Department of Medicine, University of North Carolina, Chapel Hill, NC, USA

||||| Department of Epidemiology and Biostatistics, University of California, San Francisco, CA, USA

¶¶¶ Department of Systems Biology, University of Alcalá, Madrid, Spain

Department of Orthopedics, University Medical Center Utrecht, Utrecht, the Netherlands

††††† Department of Biomechanical Engineering, Delft University of Technology, Delft, the Netherlands

ARTICLE INFO

Article history:

Received 15 July 2020

Accepted 8 December 2020

Keywords:

Coxa valga

Coxa vara

Femoroacetabular impingement

Pincer

Anatomy

Epidemiology

SUMMARY

Objective: To summarize available evidence on the association between hip shape as quantified by statistical shape modeling (SSM) and the incidence or progression of hip osteoarthritis.

Design: We conducted a systematic search of five electronic databases, based on a registered protocol (available: PROSPERO CRD42020145411). Articles presenting original data on the longitudinal relationship between radiographic hip shape (quantified by SSM) and hip OA were eligible. Quantitative meta-analysis was precluded because of the use of different SSM models across studies. We used the Newcastle–Ottawa Scale (NOS) for risk of bias assessment.

Results: Nine studies (6,483 hips analyzed with SSM) were included in this review. The SSM models used to describe hip shape ranged from 16 points on the femoral head to 85 points on the proximal femur and hemipelvis. Multiple hip shape features and combinations thereof were associated with incident or progressive hip OA. Shape variants that seemed to be consistently associated with hip OA across studies were acetabular dysplasia, cam morphology, and deviations in acetabular version (either excessive anteversion or retroversion).

Conclusions: Various radiographic, SSM-defined hip shape features are associated with hip OA. Some hip shape features only seem to increase the risk for hip OA when combined together. The heterogeneity of the used SSM models across studies precludes the estimation of pooled effect sizes. Further studies using

* Address correspondence and reprint requests to: M.M.A. van Buuren, Department of Orthopedics, Erasmus MC, University Medical Center Rotterdam, Dr. Molewaterplein 40, 3015 GD, Rotterdam, the Netherlands.

E-mail address: m.m.a.vanbuuren@erasmusmc.nl (M.M.A. van Buuren).

the same SSM model and definition of hip OA are needed to allow for the comparison of outcomes across studies, and to validate the found associations.

© 2020 The Authors. Published by Elsevier Ltd on behalf of Osteoarthritis Research Society International. This is an open access article under the CC BY license (<http://creativecommons.org/licenses/by/4.0/>).

Introduction

Hip osteoarthritis (OA) is one of the most common types of OA, and is a major contributor to the number of years lived with disability worldwide¹. Hip shape has been recognized as an important risk factor for hip OA². For this reason, the influence of hip shape has been increasingly studied over the last decade^{3–9}. Hip shape variants that are known to significantly increase the risk for hip OA are acetabular dysplasia and cam morphology^{2,7,10}. These hip shape variations are typically quantified by predefined radiological measurements such as the center-edge angle (CEA) and the alpha angle. However, other hip shape variants that are currently not captured by predefined radiological measurements may also play a role in the etiology of hip OA. The sole use of predefined measurements for hip shape analysis may therefore impede the discovery of further hip shape variants that increase the risk for hip OA.

This limitation has been partially circumvented by the emergence of statistical shape modeling (SSM)¹¹ as a novel shape analysis technique. SSM allows quantification of the whole shape of the hip and/or pelvis, in contrast to predefined measurements^{12,13}. The application of SSM yields a set of shape variants, called shape modes, that are present in the studied population. When SSM is applied to radiographic images of the hip, the association between each hip shape mode and hip OA can be measured.

SSM has been increasingly used, and many different hip shape modes have so far been associated with hip OA. However, the interpretation of the SSM shape modes can be difficult and there is no thorough overview of the related literature yet. The purpose of this systematic review was to summarize which hip shape variants were found to be associated with incident or progressive hip OA, and to determine if there are any consistent patterns of similar shape variants to be recognized across different studies.

Methods

Protocol and registration

We reported this systematic review according to the Preferred Reporting Items for Systematic Reviews and Meta-Analyses (PRISMA) guidelines¹⁴. The review protocol was first submitted to PROSPERO on September 23, 2019, and was registered on April 28, 2020 (available from: www.crd.york.ac.uk/prospero/display_record.php?ID=CRD42020145411).

Eligibility criteria

All publications presenting original research on the association between hip shape and hip OA in human adults were considered eligible, as were conference abstracts published in 2016 or later. The inclusion criteria were:

- Assessment of the longitudinal association between hip shape and OA had to be an aim of the study;
- Hip shape had to be assessed with some form of SSM;
- Hip OA should be either incident or progressive;

- The definition of hip OA could be radiological, clinical, by total hip replacement (THR) status, or a combination of those;
- Studies had to have control subjects that did not develop incident or progressive hip OA during the study.

The exclusion criteria were:

- Hip shape was measured contralaterally to the hip that developed the outcome (e.g., the shape of the contralateral hip in case of THR);
- The studied hip shape variant was explicitly described to be secondary to other conditions (e.g., childhood hip disease, trauma, avascular necrosis, tumors, previous hip surgery);
- The primary outcome was biomechanical injury, or the validation of a novel diagnostic technique;
- The OA outcome reflected 'early osteoarthritic changes', such as cartilage damage during arthroscopy or novel magnetic resonance imaging (MRI) techniques like delayed gadolinium-enhanced MRI of cartilage (dGEMRIC), Scoring Hip Osteoarthritis with MRI (SHOMRI), and T1ρ mapping.

Search and deduplication

An experienced information specialist (WB) searched the databases Embase (via Embase.com, since 1971), MEDLINE (Medline ALL via Ovid, since 1946), Web of Science Core Collection (since 1975) and the Cochrane Central Register of Trials (via Wiley, since 1992) from inception until April 25, 2020 (date last searched). A previously published method was used for search development and optimization¹⁵. The searches combine terms (both thesaurus terms where available, and terms in title and/or abstract) for hip osteoarthritis with terms for anatomy or morphology and terms for risk or pathology. Search results were limited to exclude (1) animal and child-only studies, (2) conference abstracts published before 2016, and (3) publications in other languages than English. The full search strategy can be found in [Supplement 1](#). Additionally, we searched Google Scholar and screened the reference lists of the included references for any other relevant articles. The search results from all databases were imported in EndNote and deduplicated¹⁶.

Study selection

Two reviewers (MvB and RA) independently screened the titles and abstracts of all search results, and after having compared the included references, independently reviewed the full text of all potentially eligible studies. This process was done in EndNote with a predefined method¹⁷. Subsequently the reviewers held a consensus meeting to discuss each full-text article separately, and to select the final studies to be included. A third reviewer (MN) was consulted to resolve any disagreements.

Data collection/extraction

A custom open-ended electronic data extraction form was developed and pilot-tested with a sample of the included studies. The used data extraction form, including the full list of extracted

variables, can be found in [Supplement 2](#). Data extraction was independently performed in duplicate by two reviewers (MvB and RA), and the results were compared in a consensus meeting. For one conference abstract of which the full text was not published yet, the reviewers requested and received the full text manuscript from the authors.

Risk of bias assessment

We used the Newcastle–Ottawa Scale (NOS) to assess the risk of bias of the individual studies¹⁸. We used either the cohort version or the case–control version as appropriate. The questions and the scoring key can be found in [Supplement 3](#). The two reviewers (MvB and RA) independently appraised the quality of the individual studies, and disagreements were resolved in a consensus meeting. Publication bias was reduced by searching for recent conference abstracts and by searching Google Scholar for gray literature.

Statistical shape analysis

The application of SSM requires all images (e.g., radiographs) to be annotated by placing a set of points around the outline of the bone. To negate the effect of size and orientation, the outline of the bone (the shape) across images is usually aligned first using a technique called Procrustes analysis. Principal component analysis (PCA) is then applied to identify the main variations in shape (called shape modes) within the given population (i.e., across all images), summarized as a statistical shape model. Shape modes are stored as a set of continuous variables, usually standardized to have a mean of 0 and a standard deviation of 1, and are linearly independent of each other. These shape modes represent the apparent radiographic shape, and may not always match the true anatomic shape due to the influence of subject positioning and radiographic projection effects. Shape modes are ordered by their contribution to the total shape variance, the lower mode numbers being the most contributing. Because the SSM process arbitrarily assigns deviations from the mean shape as either positive or negative, a certain shape variant can either be positively or negatively (inversely) associated with the outcome. Furthermore, due to the nature of PCA the definition of individual shape modes will be data dependent and thus will vary across datasets/studies.

Data synthesis

The main outcome measures that we extracted were the measures of association for the relationship between SSM-defined hip shape and OA. These could be odds ratios (OR), relative risk (RR), prevalence ratios (PR), or any other association measures. If present, the covariate-adjusted measures were extracted. We only performed qualitative data synthesis, as the use of SSM models resulting from different studies precludes statistical pooling and thus meta-analysis. To still be able to summarize associations, we qualitatively compared the descriptions (as provided in the original papers) of the different hip shape modes from across studies. The reported shape descriptions are therefore either the literal descriptions by the original authors, or the reviewers' interpretation of the original figures if these were unambiguous. If neither was the case, we did not report a shape description.

Results

Study selection

The initial database searches yielded 4,618 unique references, which were screened by title and abstract. Twenty-five of these had used SSM to quantify hip shape and were retrieved for full-text reading. The screening and inclusion process as well as the reasons for exclusion are shown in [Fig. 1](#). Finally, we included nine articles in this review^{19–27}.

Study characteristics

The main characteristics of the nine included studies (published between 2007 and 2017) are presented in [Table I](#). The study by Mezhov *et al.*²⁷ has only been published as a conference abstract as of yet, but we received the full manuscript from the authors upon request. The included studies present data on a total population of 4,706 subjects, with 6,483 hips analyzed with SSM. Not all subjects were unique, since some parts of study populations were used in two separate articles^{20,23,25,27}. The Rotterdam Study population was also used twice, but random samples were drawn, making duplicate entry of subjects unlikely^{19,24}. Factoring in the use of data from these study populations in separate articles, the number of unique hips analyzed with SSM was 4,584. Median sample size was 664 subjects (range 110–831) and median follow-up period was 6.5 years (range 5–19). The overall proportion of females was 69.0%, ranging from 51%^{23,27} to 100%^{20,26}. The mean age of included subjects ranged from 53.6²⁰ to 70.7²⁶, with a pooled mean age of 61.8 years across all studies.

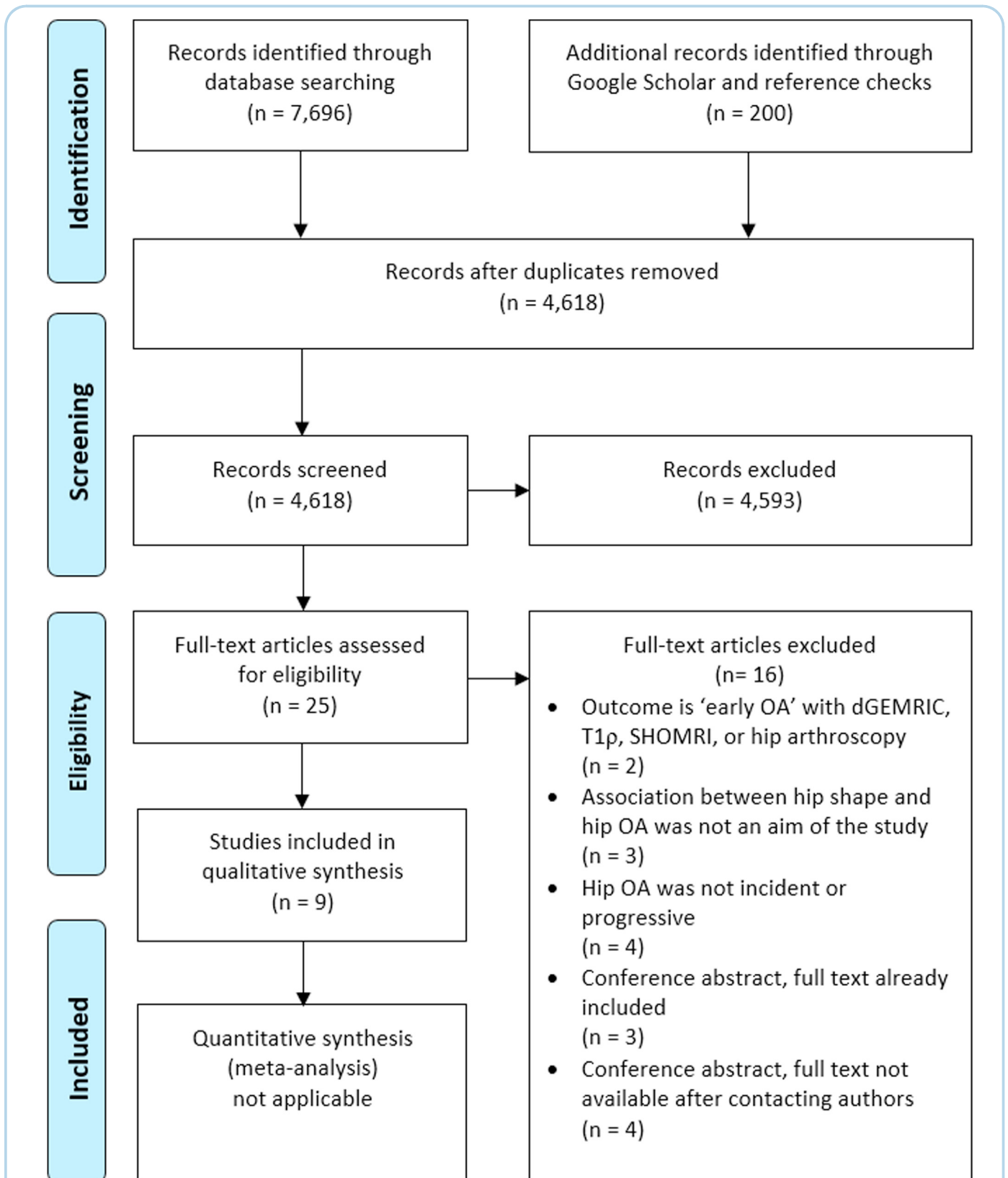
Risk of bias

A summary of the risk of bias assessment is presented in [Table II](#), whereas an extensive overview can be found in [Supplement 2](#). Eight of the included studies were deemed as having good methodological quality, with a low risk of bias^{19–22,24–27}. When strictly following the NOS guidelines, one study scored poorly because of self-reported THR assessment and the lost to follow-up rate²³. However, the reviewers considered the overall quality of this study sufficient to regard the findings as reliable.

Assessment of exposure and outcome

An overview of the assessment of exposure and outcome in each study can be found in [Table III](#). Seven studies^{19–22,24–26} used pelvic radiographs to assess hip shape, whereas the other two^{23,27} used Dual-energy X-ray absorptiometry (DXA). The SSM points used to outline the hip shape varied from 16¹⁹ to 85^{23,27}. Three studies only described the femoral head¹⁹ or part of the proximal femur^{21,26}. Three studies additionally included the acetabular roof^{22,23,27}. The remaining three studies also included the ipsilateral lower pelvis, consisting of the acetabulum, the pelvic teardrop, and the pubic and ischial bones^{20,24,25}. All studies^{19–27} used the ASM toolkit (University of Manchester, Manchester, UK) to annotate the images. Seven studies also used this toolkit to create the SSM, while two studies^{23,27} additionally used SHAPE software (University of Aberdeen, Aberdeen, UK) for this. Both the ASM toolkit and the SHAPE software are based on Procrustes analysis and PCA.

Eight studies^{19,20,22–27} used THR as a definition for hip OA. Other used definitions were Kellgren–Lawrence (KL) grade ≥ 2 ^{21,24}, an increase in KL grade of ≥ 3 points compared to baseline¹⁹, Croft

**Fig. 1**

PRISMA flow diagram detailing the literature search, screening and inclusion process. PRISMA, Preferred Reporting Items for Systematic Reviews and Meta-Analyses; OA, osteoarthritis; dGEMRIC, delayed gadolinium-enhanced magnetic resonance imaging of cartilage; SHOMRI, scoring hip osteoarthritis with magnetic resonance imaging.

Study	Country	Study population	Study design	N subjects	N hips	Age in years, mean (SD)	% Females	Mean follow-up
Agricola et al. (2015) ²⁰	Netherlands	CHECK study	Prospective cohort	550	1,100	55.8 (5.1)	100%	5 years
	UK	Chingford study	Nested case-control	114	114	53.6 (5.4)	100%	19 years
Agricola et al. (2013) ²⁵	Netherlands	CHECK study	Prospective cohort	723	1,411	55.9 (5.2)	79%	5 years
Ahedi et al. (2017) ²³	Australia	TASOAC study	Prospective cohort	831	831	63.2 (7.5)	51%	10 years
Barr et al. (2012) ²²	UK	PCR study	Nested case-control	195	102	62.7 (10.7)	68%	5 years
Castaño-Betancourt et al. (2013) ²⁴	Netherlands	Rotterdam Study	Prospective cohort	688	1,283	65.6*	58%	6.5 years
Gregory et al. (2007) ¹⁹	Netherlands	Rotterdam Study	Nested case-control	110	110	68.7 (5.9)†	75%	6 years
Lynch et al. (2009) ²⁶	USA	SOF	Nested case-control	351	351	70.7 (4.4)†	100%	8.3 years
Mezhov et al. ²⁷	Australia	TASOAC study	Prospective cohort	802	799	62.5 (7.3)†	51%	12.1 years
Nelson et al. (2014) ²¹	USA	JoCoOA project	Nested case-control	342	382	61.7 (9.0)	61%	6 years

UK, United Kingdom; USA, United States of America; CHECK, Cohort Hip and Cohort Knee; TASOAC, Tasmanian Older Adults Cohort; PCR, Primary Care Rheumatology; SOF, Study of Osteoporotic Fractures; JoCoOA, Johnston County Osteoarthritis; SD, standard deviation.

* No measure of variability was reported.

† Pooled mean and SD calculated by reviewers.

Table 1 Characteristics of the nine included studies

Osteoarthritis
and Cartilage

grade ≥ 2 ²⁶, and meeting the American College of Rheumatology (ACR) criteria²⁵. Some studies included multiple definitions of hip OA, either creating subgroups per outcome definition^{19,25} or pooling multiple definitions into one group^{24,26}. Six studies^{19–21,24–26} used incident hip OA as the outcome, meaning all cases had baseline OA scores (e.g., KL, Croft) of 0–1. In the remaining three studies^{22,23,27}, the distinction between incidence and progression could not be made because part of the study sample already had OA scores ≥ 2 at baseline. All studies corrected for two or more covariates in their analyses^{19–26}.

The association between hip shape and THR

The results from the studies that used THR as a separate outcome definition^{19,20,22,23,25,27} are summarized in Table IV, whereas the complete results (including non-significant associations) can be found in Supplement 2. All six studies that used THR as a separate outcome measure found at least one shape mode that was statistically significantly associated with THR (median 2 modes, range 1–6) at the chosen alpha level. The indication for THR was incident hip OA in three studies^{19,20,25}, and incident or progressive hip OA in the other three studies^{22,23,27}. One study²⁵ used Bonferroni correction for multiple testing.

A total of 18 hip shape modes were associated with future THR across the different studies. One of these modes (describing a flattened head–neck junction, a flat major trochanter and a prominent acetabular posterior wall) showed a consistent association in two different populations, namely the CHECK and Chingford populations²⁰. Five studies^{19,20,23,25,27} (out of the six that used THR as a separate outcome measure) found at least one shape mode consistent with cam morphology; and four^{20,22,23,27} out of six studies found a mode representing acetabular dysplasia. A hip shape variant possibly representing pincer morphology was associated with THR in one study²⁵ out of the six studies that included the acetabular roof in their model^{20,22–25,27}. The description of this shape mode was “more pronounced lateral acetabular rim” in this study. Deviations in acetabular version were associated with THR in both studies that included the acetabulum in their shape model^{20,25}. One study describes a shape mode with “a prominent acetabular posterior wall”, possibly representing excessive acetabular anteversion, combined with “a flattened head–neck junction and a flat major trochanter”²⁰. The other study describes

a mode with “acetabular retroversion”, combined with a “flat head–neck junction and broad femoral neck”²⁵.

The association between hip shape and radiographic hip OA

Studies that mainly used radiographic hip OA as outcome measure^{19,21,24,26} are summarized in Table V, whereas the complete results (including non-significant associations) can be found in Supplement 2. At least one shape mode per study was statistically significantly associated with hip OA (median 3 modes, range 1–6) at the chosen alpha level. In all four studies the outcome was incident hip OA (baseline OA scores of 0–1). Two studies^{24,26} used a combined definition of hip OA, where THR and radiographic hip OA were pooled into a single endpoint. However, one of those studies only seemed to present radiographic hip OA cases in their results, and no THRs²⁴. Two studies^{24,26} used Bonferroni correction for multiple testing.

Thirteen hip shape modes were associated with incident radiographic hip OA. One study²¹ presented two hip shape modes that showed different associations in different subgroups. In this study, mode 2 (representing alterations in the transition between greater trochanter and femoral neck and femoral neck length and thickness) was inversely associated with symptomatic radiographic hip OA in the entire study population, but positively associated with radiographic hip OA in males only. Positive mode 2 scores represented flattening of the femoral head, suggestive of cam morphology. Two^{19,21} out of four studies found shape modes representing cam morphology; and the only study that included the acetabulum in their model²⁴ found shape modes representing dysplasia. Acetabular version was also associated with radiographic hip OA in that study, but the type (ante- or retroversion) was unspecified²⁴.

The association between hip shape and clinical hip OA

One study²⁵ used a clinical definition of hip OA, namely the ACR criteria, next to another definition (THR). They found no statistically significant associations between baseline hip shape modes and ACR criteria at follow-up. Another study²¹ made the distinction between symptomatic radiographic hip OA and overall radiographic hip OA. This study found associations between different shape modes and symptomatic radiographic hip OA in the overall

Study	NOS version	Selection	Comparability	Exposure/Outcome	Total stars	Quality Score†
Agricola et al. (2015) ²⁰	Case-Control*	★★★★	★★	★★★	9	Good
	Cohort*	★★★★	★★	★★★	9	Good
Agricola et al. (2013) ²⁵	Cohort	★★★★	★★	★★★	9	Good
Ahedi et al. (2017) ²³	Cohort	★★★★	★★	☆☆☆	7	Poor
Barr et al. (2012) ²²	Case-Control	☆☆☆	★★	☆☆☆	7	Good
Castaña-Betancourt et al. (2013) ²⁴	Cohort	★★★★	★★	★★★	9	Good
Gregory et al. (2007) ¹⁹	Case-Control	★★★★	☆☆	★★★	8	Good
Lynch et al. (2009) ²⁶	Case-Control	☆☆☆	★★	★★★	8	Good
Mezhov et al. ²⁷	Cohort	★★★★	☆☆	☆☆☆	7	Good
Nelson et al. (2014) ²¹	Case-Control	★★★★	★★	★★★	9	Good

See Supplement 2 for the reviewers' considerations for each question. See Supplement 3 for score calculation. NOS, Newcastle–Ottawa Scale.

* Two versions of NOS were used: NOS case-control for the Chingford population, and NOS cohort for the Cohort Hip and Cohort Knee population.

† The table shows the stars earned for each domain, and the total amount of stars.

Table II Newcastle–Ottawa Scale for risk of bias assessment

Osteoarthritis
and Cartilage

Study	Exposure assessment				Outcome assessment		
	Imaging modality	N points in SSM model	Anatomical regions included in SSM model	Software used for SSM	Protocol pelvic radiograph	Hip OA definition	Hip OA type
Agricola et al. (2015) ²⁰	X-ray	75 ^a	Proximal femur and lower pelvis	ASM toolkit	AP weight-bearing, 15° IR ¹ AP supine, neutral ²	THR	Incident
Agricola et al. (2013) ²⁵	X-ray	75 ^a	Proximal femur and lower pelvis	ASM toolkit	AP weight-bearing, 15° IR	THR/ACR criteria*	Incident
Ahedi et al. (2017) ²³	DXA	85 ^b	Proximal femur and acetabular roof	ASM toolkit + SHAPE	AP weight-bearing, 10° IR	THR	Incident & progressive
Barr et al. (2012) ²²	X-ray	16 ^c 45	Femoral head and superior neck Proximal femur and acetabular roof	ASM toolkit	AP unspecified	THR	Incident & progressive
Castaña-Betancourt et al. (2013) ²⁴	X-ray	67	Proximal femur and lower pelvis	ASM toolkit	AP weight-bearing, 10° IR	THR/KL ≥ 2**	Incident
Gregory et al. (2007) ¹⁹	X-ray	16 ^c	Femoral head and superior neck	ASM toolkit	AP weight-bearing, 10° IR	THR/KL increase of ≥ 3 points*	Incident
Lynch et al. (2009) ²⁶	X-ray	60 ^d	Proximal femur	ASM toolkit	AP supine, 15–30° IR	THR/Croft ≥ 2**	Incident
Mezhov et al. ²⁷	DXA	85 ^b	Proximal femur and acetabular roof	ASM toolkit + SHAPE	AP weight-bearing, 10° IR	THR	Incident & progressive
Nelson et al. (2014) ²¹	X-ray	60 ^d	Proximal femur	ASM toolkit	AP supine, 15° IR	KL ≥ 2	Incident

a,b,c,d These pairs of studies used the same point set for annotation; ¹Protocol used in Cohort Hip and Cohort Knee (CHECK); ²Protocol used in Chingford cohort; *These studies used two definitions for hip OA and performed subgroup analyses for the separate outcomes; **These studies used two definitions for hip OA and pooled these into one group; SSM, statistical shape modeling; OA, osteoarthritis; DXA, Dual-energy X-ray Absorptiometry; ASM, Active Shape Modelling; AP, anteroposterior; IR, internal rotation; THR, total hip replacement; KL, Kellgren–Lawrence grade, ACR, American College of Rheumatology criteria for hip OA.

Table III Overview of the exposure and outcome assessments used in the included studies

Osteoarthritis
and Cartilage

Study	Association measure	Subgroup	Shape mode	Explained variance	Shape that is associated with total hip replacement*	Effect size (95% CI)	P-value	Alpha level	Covariates
Agricola et al. (2013) ²⁰	OR	Chingford	2	–	<i>Longer and narrower femoral neck</i>	1.61 (1.02–2.54)	0.042	0.05	–
			17	–	Flattened head–neck junction, a flat major trochanter and a prominent acetabular posterior wall	0.41 (0.23–0.82)	0.01		
			4	–	Non-spherical femoral head, together with a shallow acetabulum	0.38 (0.20–0.69)	0.002	0.05	Age BMI Baseline KL
			11	–	<i>Smaller femoral head, smaller major trochanter</i>	2.18 (1.23–3.86)	0.008		
			15	–	Orientation of pelvis & greater trochanter	1.66 (1.02–2.68)	0.04		
			17	–	<i>More medial projection of greater trochanter</i>	0.51 (0.33–0.80)	0.003		
			22	–	Flattened head–neck junction, a flat major trochanter, and a prominent acetabular posterior wall	1.90 (1.29–2.78)	0.001		
Agricola et al. (2013) ²⁵	OR	Overall	7	–	Shorter femoral neck	0.54 (0.38–0.78)	0.001	0.002	Age BMI Gender
			11	–	Flat head–neck junction, broad femoral neck, acetabular retroversion	1.78 (1.28–2.47)	0.001		
			12	–	<i>Less superior joint space width, more pronounced lateral acetabular rim</i>	2.10 (1.46–3.04)	<0.001		
			15	–	Wider femoral neck, less head-neck offset	1.90 (1.39–2.59)	<0.001		
			22	–	<i>Not described, not shown in figures</i>	0.59 (0.42–0.81)	0.001		
Ahedi et al. (2017) ²³	PR	Overall	2	14.0%	Greater neck-shaft angle, narrower femoral neck, smaller & flatter femoral head, less acetabular coverage	1.60 (1.20–2.15)	<0.05**	0.05	Age BMI Gender
			4	6.0%	Wider femoral neck, larger femoral head, larger joint space width, loss of sphericity at transition superior neck to head (pistol-grip deformity)	0.63 (0.50–0.84)	<0.05**		
Barr et al. (2012) ²²	OR	45-point model	2	–	Poor acetabular coverage, steeper neck-shaft angle	0.17 (0.04–0.71)	<0.05**	0.05	Baseline KL Clinical factors‡ Geometrical factors‡
Gregory et al. (2007) ¹⁹	OR	Overall	3	–	Sharp transition from femoral head to the upper neck	3.71 (1.33–10.4)§	0.012	0.05	Age Gender
			6	–	Less pronounced curve from upper femoral neck into the head, sharper transition from femoral head to the lower neck	2.35 (1.15–4.82)§	0.019		
Mezhov et al. ²⁷	RR	Overall	2	–	Decreasing acetabular coverage	1.57 (1.01–2.46)	<0.05**	0.05	WOMAC pain
			4	–	Non-spherical femoral head	0.65 (0.44–0.97)	<0.05**		OARSI grade

*These shapes are positively associated with the outcome, unless stated otherwise. For a visual impression of what these shape modes look like, we refer to the original articles. Effect sizes are shown per 1 SD increase in shape mode value. An effect size ratio between 0 and 1 indicates that the negative SDs are associated with the outcome, and ratios above 1 indicate that positive SDs are associated with the outcome. Descriptions in regular typeface are taken literally from the original papers, while descriptions in italics are interpreted from the figures of the original papers; **Exact P-values were not given, but were under the alpha level of 0.05; †Clinical factors: use of a stick, physical function (from WOMAC), duration of pain; ‡Geometrical factors: acetabular depth, center-edge angle, baseline minimum joint space width and femoral head migration; §ORs are for OA with THR vs OA without THR; CI: confidence interval; OR: odds ratio; PR: prevalence ratio; RR: relative risk; CHECK: Cohort Hip and Cohort Knee; BMI: body mass index; KL: Kellgren–Lawrence grade; WOMAC: Western Ontario and McMaster Universities Osteoarthritis Index; OARSI: Osteoarthritis Research Society International; SD: standard deviation.

Table IV Hip shape modes significantly associated with total hip replacement outcome

Study	Association measure	Subgroup	Shape mode	Explained variance	Shape that is associated with radiographic hip osteoarthritis*	Effect size (95% CI)	P-value	Alpha level	Covariates
Castaño-Betancourt et al. (2013) ²⁴	OR	Overall ^a	5	–	Less covering of the femoral head by the acetabulum	0.65 (0.54–0.77)	<0.0001	0.0021	Age Gender BMI
			9	–	Shorter femoral neck	1.40 (1.14–1.72)	0.001		
			12	–	Variation in acetabular version with corresponding rotation of the femur†	1.69 (1.24–2.30)	0.00094		
Gregory et al. (2007) ¹⁹	OR	Overall	6	–	Less pronounced curve from upper femoral neck into the head, sharper transition from femoral head to the lower neck	1.62 (1.08–2.45)	0.02	0.05	Age Gender
Lynch et al. (2009) ²⁶	OR	Overall ^b	3	8.9%	Larger femoral head, longer and thinner femoral neck relative to the size of the trochanters and shaft	1.73 (1.25–2.39)	<0.001	0.005	Age Height Hip BMD
			5	3.3%	Larger than average greater trochanter size, smaller femoral neck size relative to the average size of the femoral head and shaft	2.31 (1.63–3.28)	<0.001		
			9	0.8%	Large femoral head compared to femoral neck, more pronounced greater trochanter	1.81 (1.32–2.49)	<0.001		
Nelson et al. (2014) ²¹	OR	Overall	2	16.0%	Alterations in the transition between greater trochanter and femoral neck, a slight reduction in femoral neck width, and a qualitative impression of a longer femoral neck compared to the mean shape	1.47 (1.03–2.08)§	<0.05**	0.05	Age Gender BMI Race Baseline KL
			3	12.5%	Alterations in the transition between greater trochanter and femoral neck, a somewhat flatter femoral head	1.54 (1.09–2.17)§	<0.05**		
			1	37.4%	Larger trochanter, flatter trochanter, a flattening of the transition between femoral head and neck	1.66 (1.11–2.48)	<0.05**		
			2	16.0%	Flattening of the femoral head, somewhat suggestive of cam-type change of femoroacetabular impingement	1.49 (1.01–2.19)	<0.05**		
			6	3.4%	Subtle differences in the size of the greater trochanter, the length of the femoral neck, and the transition between the two†‡	2.11 (1.28–3.50)§	<0.05**		
			14	0.6%	<i>Not described, not shown in figures</i>	1.80 (1.06–3.07)§	<0.05**		
			6	3.4%	Subtle differences in the size of the greater trochanter, the length of the femoral neck, and the transition between the two†‡	1.94 (1.20–3.11)§	<0.05**		
			11	1.1%	Alterations in the transition between greater trochanter and femoral neck	1.52 (1.05–2.17)§	<0.05**		
			6	3.4%	Subtle differences in the size of the greater trochanter, the length of the femoral neck, and the transition between the two†‡	1.94 (1.20–3.11)§	<0.05**		

*These shapes are positively associated with the outcome, unless stated otherwise. For a visual impression of what these shape modes look like, we refer to the original articles. Effect sizes are shown per 1 SD increase in shape mode value. An effect size ratio between 0 and 1 indicates that the negative SDs are associated with the outcome, and ratios above 1 indicate that positive SDs are associated with the outcome. Descriptions in regular typeface are taken literally from the original papers, while descriptions in italics are interpreted from the figures of the original papers; **Exact P-values were not given, but were under the alpha level of 0.05; ^aThis study described a combined outcome definition (THR or KL ≥ 2) in their methods, but only presented KL ≥ 2 cases in their results; ^bThis study used a combined outcome definition (THR or Croft ≥ 2); †This study did not describe what the actual differences between positive and negative SDs were; ‡In the group *with* baseline symptoms a decrease in mode 6 score was associated with the outcome, while in the group *without* baseline symptoms an increase in mode 6 score was associated with the outcome; §OR for symptomatic radiographic hip osteoarthritis; CI: confidence interval; OR: odds ratio; KL: Kellgren–Lawrence grade; BMI: body mass index; BMD: bone mineral density; SD: standard deviation.

Table V Hip shape modes significantly associated with radiographic hip osteoarthritis outcomes

population, as well as in subgroups with or without baseline symptoms (Table V).

Discussion

In this systematic review we have summarized all available evidence from the published literature on the association between SSM-defined apparent radiographic hip shape and hip OA. Our results show that every published study on this topic that was included in this review found at least one hip shape mode statistically significantly associated with incident or progressive hip OA or future THR. Most studies found multiple (up to six) linearly independent hip shape modes associated with hip OA. Most of the included studies used different populations and different SSM point positions for their modeling, which complicates the comparison of hip shape modes between studies. However, in the following we attempt to discuss the overall patterns in radiographic hip shape that were found to be associated with hip OA.

Shape variants that likely represent cam morphology and acetabular dysplasia were consistently found to be associated with future THR and/or incidence or progression of radiographic hip OA. Shape modes that might represent cam morphology were described as “cam-type change of femoroacetabular impingement”²¹, “pistol-grip deformity”²³, “less concavity of superior head–neck junction”²⁵, “less pronounced curve from upper femoral neck into the head”¹⁹, “less head-neck offset”²⁵, “non-spherical femoral head”^{20,23,27}, “flattening of the head-neck transition”²¹, and “flattening of the femoral head”²¹. Modes that may represent acetabular dysplasia were described as “less/poor/decreasing acetabular coverage”^{22–24,27}, and “a shallow acetabulum”²⁰. The associations between hip OA and both cam morphology and acetabular dysplasia have already been proven in other studies that used traditional measurements, such as the alpha angle and the CEA^{7,8,10,28–35}. Two cross-sectional studies that used SSM also found associations between cam morphology and the presence of hip OA^{36,37}. These studies were not included in our systematic review due to their cross-sectional design. Because there were no baseline OA measurements, it remains unclear whether the shape modes found in these studies preceded hip OA or resulted from it.

A shape mode possibly representing pincer morphology was also associated with THR in one of the studies included in this review²⁵. Other studies, using traditional measurements such as the CEA and the crossover sign, did not find a positive association between pincer morphology and hip OA so far^{7,8,10}. Maybe the risk for hip OA is only increased when a pincer morphology is mixed with other shape features, or for certain subtypes of pincer morphology that are not captured with traditional measurements. A cross-sectional study³⁶ (excluded from our systematic review) also found an association between pincer morphology and hip OA. In the shape mode of that particular study, the “pincer-type variation” was combined with a “larger femoral head and wider femoral neck”. This combination could theoretically aggravate femoroacetabular impingement. However, since no baseline OA measurements were done in this study, the “pincer-type variation” shape mode could have also represented an osteophyte of the lateral acetabulum, secondary to hip OA.

Multiple studies included in this systematic review found associations between acetabular version and hip OA. This is in line with studies using traditional measurements, which have also suggested that both acetabular anteversion and retroversion could be associated with hip OA^{38–40}. A cross-sectional study that used SSM to define hip shape also found associations between two shape modes, possibly representing acetabular retroversion and anteversion respectively, and the presence of hip OA⁴¹.

Because one statistical shape mode often consists of more than one shape feature, extra caution has to be taken when singling out just one shape feature. The association with hip OA may only be present when there is a combination of multiple shape features. This is precisely the advantage of SSM. One combination that consistently appears to be associated with hip OA is cam morphology combined with dysplastic acetabular features^{20,25}, a combination that has been previously described in the literature^{42,43}. It is still not entirely clear why this combination would increase the risk for hip OA, because theoretically a cam would be less likely to impinge with a dysplastic acetabulum. However, one computer simulation study has demonstrated that impingement can still occur, but more proximally and more medially than with a normal acetabulum⁴⁴. It remains unknown whether the higher risk is due to the cam morphology alone, the dysplastic acetabulum, or the interaction between the two. Another reported shape combination was the presence of a cam morphology with acetabular retroversion²⁵, which could be theoretically explained by femoroacetabular impingement happening earlier during hip flexion and internal rotation. The combination of a valgus hip with acetabular dysplasia^{22,23} was associated with hip OA in two studies. From a biomechanical perspective, this could be explained by higher vertical joint reaction force⁴⁵ acting on a smaller surface during weight bearing. This combination has also been previously described⁴³. Besides the aforementioned combinations, variations in the size of the trochanters, the length and width of the femoral neck, and the apparent rotation of the femur and pelvis were found, but no obvious patterns were seen in these variations.

The magnitude of the reported associations between hip shape modes and hip OA varied greatly between studies. Due to the different SSM point positions and different outcome definitions, the association measures are not directly comparable. Large ORs or RRs can be interpreted as a strong association nevertheless.

Strengths and limitations

This is the first systematic review on the association between SSM-defined radiographic hip shape and hip OA. It offers an overview of the patterns of hip shape features that are associated with hip OA in multiple populations. The interpretation and implications of the results were carefully discussed within the review group, which contains experts in the fields of both hip OA and SSM. Strengths of the included studies are the relatively large sample sizes and the various populations of differing ages and ethnicities that were included. Overall, the included studies scored well on methodological quality.

One limitation of this review is that we were not able to conduct a meta-analysis. This is inherent to SSM, because the shape modes will be defined by the population from which they were created. This was already taken into account when designing the review protocol. The lack of a meta-analysis makes validation of associations difficult. We therefore subjectively described patterns of hip shape that seemed to be consistently associated with hip OA across the included studies. A second limitation is that the interpretation and description of the shape modes are relatively subjective processes, which were left to the authors of the included papers. Still, we purposefully reported only the literal descriptions from the original articles to reduce bias by our own interpretation. Another limitation is that none of the included studies have validated the found associations in an independent test dataset. Internal validation would have been possible if the datasets had been divided into a training set and a test set. This is something that future SSM studies could possibly address. One more consideration is the influence that hip OA may have on hip shape. As some studies have shown, hip OA may not only result from certain hip shape variants

but can also cause changes in hip shape⁴⁶. This is not a problem in incidence studies^{19–21,24–26} where all analyzed hips were free of OA at baseline, but the hip shape modes found in progression studies^{22,23,27} could already be a result of early hip OA. Further limitations of the included studies are the heterogeneity of pelvic radiograph protocols and outcome definitions, and the varying use of covariate adjustment. Further research is required to investigate whether significant covariates (e.g., gender) may require independent shape models instead of simply adjusting for them. Lastly, most studies only described shape modes that were significantly associated with hip OA at their chosen alpha level, but some studies used Bonferroni correction, whereas others did not. This may have led to some reporting bias, even more so because statistical significance does not always translate to clinical significance. In our opinion, the use of multiple testing correction in SSM analysis should depend on the goal of the analysis. When SSM is used for hypothesis generation, you could argue not using a correction because you would want to find any possible leads. The associations found in this way should not be taken as evidence though, but have to be investigated further. In other cases, a method like the Bonferroni correction is warranted. In any case, authors should preferably explain their reasoning for (not) using multiple testing correction.

Conclusion

This systematic review suggests that several radiographic hip shape features and combinations thereof are associated with the incidence or progression of radiographic hip OA and with future THR. Associations of both cam morphology and acetabular dysplasia with hip OA have been found by SSM in multiple studies. In addition, hip shape features other than these well-known variants also appear to be associated with hip OA. Moreover, certain combinations of (sometimes subtle) hip shape features, rather than single features, may increase the risk for development or progression of hip OA when present together. More research with SSM is needed to validate these associations, and a standardized set of SSM point positions should be used to allow comparison between studies. When SSM is used to generate hypotheses, the found associations could be tested with traditional radiographic measurements in an independent sample. This would both validate the associations and make them more easily transferrable to clinical practice.

Author contributions

Conception and design: MvB, NA, SBZ, WB, JM, AN, MN, RA.
 Screening of abstracts and full texts: MvB, RA.
 Collection and assembly of data: MvB, RA.
 Analysis and interpretation of the data: MvB, NA, SBZ, NC, DF, GJ, NL, CL, NM, JM, AN, MN, PV, JV, HW, RA.
 Statistical expertise: MvB, CL, RA.
 Drafting of the article: MvB, WB, RA.
 Critical revision of the article for important intellectual content: MvB, NA, SBZ, WB, NC, DF, GJ, NL, CL, NM, JM, AN, MN, PV, JV, HW, RA.
 Final approval of the article: MvB, NA, SBZ, WB, NC, DF, GJ, NL, CL, NM, JM, AN, MN, PV, JV, HW, RA.

Conflict of interest statement

Within the submitted work: MvB reports a research grant from the Dutch Arthritis Society (18-2-203). CL reports a research grant from the Medical Research Council, UK (MR/S00405X/1). MN reports a research grant from NIH. HW reports a research grant from the European Union.

Outside the submitted work: NA reports personal fees from Pfizer and Eli Lilly and Company, with research grants from Merck. SBZ reports personal fees from Pfizer and Osteoarthritis and Cartilage, with research grants from the European Union, The Netherlands Organisation for Health Research and Development, the Dutch Arthritis Society, and Foreum. GJ reports personal fees from BMS, Roche, Abbvie, Amgen, Eli Lilly and Company, Novartis, Janssen, with research grants from Covance. AN reports personal fees from GSK, Flexion Therapeutics, MedScape and Health Press Ltd. HW reports research grants from the European Union, the Dutch Arthritis Society, and the Dutch Government. RA reports a research grant from the Dutch Arthritis Society.

The remaining authors report no competing interests.

Role of the funding source

The funding sources had no role in study design, in collection, analysis, and interpretation of the data, nor in the preparation of the manuscript or the decision to submit the manuscript for publication.

Acknowledgments

No further contributors need to be acknowledged. No writing assistance was used.

Supplementary data

Supplementary data to this article can be found online at <https://doi.org/10.1016/j.joca.2020.12.003>.

References

- Cross M, Smith E, Hoy D, Nolte S, Ackerman I, Fransen M, *et al*. The global burden of hip and knee osteoarthritis: estimates from the global burden of disease 2010 study. *Ann Rheum Dis* 2014;73:1323–30, <https://doi.org/10.1136/annrheumdis-2013-204763>.
- Sandell LJ. Etiology of osteoarthritis: genetics and synovial joint development. *Nat Rev Rheumatol* 2012;8:77–89, <https://doi.org/10.1038/nrrheum.2011.199>.
- Bouyer B, Mazieres B, Guillemin F, Bouttier R, Fautrel B, Morvan J, *et al*. Association between hip morphology and prevalence, clinical severity and progression of hip osteoarthritis over 3 years: the knee and hip osteoarthritis long-term assessment cohort results. *Joint Bone Spine* 2016;83:432–8, <https://doi.org/10.1016/j.jbspin.2015.09.005>.
- Nelson AE. The importance of hip shape in predicting hip osteoarthritis. *Curr Treatm Opt Rheumatol* 2018;4:214–22, <https://doi.org/10.1007/s40674-018-0096-0>.
- Nelson AE, Stiller JL, Shi XA, Leyland KM, Renner JB, Schwartz TA, *et al*. Measures of hip morphology are related to development of worsening radiographic hip osteoarthritis over 6 to 13 year follow-up: the Johnston County Osteoarthritis Project. *Osteoarthr Cartil* 2016;24:443–50.
- Nicholls AS, Kiran A, Pollard TC, Hart DJ, Arden CP, Spector T, *et al*. The association between hip morphology parameters and nineteen-year risk of end-stage osteoarthritis of the hip: a nested case-control study. *Arthritis Rheum* 2011;63:3392–400, <https://doi.org/10.1002/art.30523>.
- van Klij P, Heerey J, Waarsing JH, Agricola R. The prevalence of cam and pincer morphology and its association with development of hip osteoarthritis. *J Orthop Sports Phys Ther* 2018;48:230–8, <https://doi.org/10.2519/jospt.2018.7816>.
- Saberi Hosnijeh F, Zuiderwijk ME, Versteeg M, Smelee HTW, Hofman A, Uitterlinden AG, *et al*. Cam deformity and

- acetabular dysplasia as risk factors for hip osteoarthritis. *Arthritis Rheum* 2017;69:86–93, <https://doi.org/10.1002/art.39929>.
9. Zeng WN, Wang FY, Chen C, Zhang Y, Gong XY, Zhou K, et al. Investigation of association between hip morphology and prevalence of osteoarthritis. *Sci Rep* 2016;6:23477, <https://doi.org/10.1038/srep23477>.
 10. Agricola R, Heijboer MP, Roze RH, Reijman M, Bierma-Zeinstra SMA, Verhaar JAN, et al. Pincer deformity does not lead to osteoarthritis of the hip whereas acetabular dysplasia does: acetabular coverage and development of osteoarthritis in a nationwide prospective cohort study (CHECK). *Osteoarthr Cartil* 2013;21:1514–21, <https://doi.org/10.1016/j.joca.2013.07.004>.
 11. Cootes TF, Taylor C, Cooper D, Graham J. Active shape models – their training and application. *Comput Vis Image Und* 1995;61:38–59, <https://doi.org/10.1006/cviu.1995.1004>.
 12. Lindner C, Thiagarajah S, Wilkinson JM, Consortium Ta, Wallis GA, Cootes TF. Fully automatic segmentation of the proximal femur using random forest regression voting. *IEEE Trans Med Imag* 2013;32:1462–72, <https://doi.org/10.1109/TMI.2013.2258030>.
 13. Lindner C, Thiagarajah S, Wilkinson JM, Consortium Ta, Wallis GA, Cootes TF. Development of a fully automatic shape model matching (FASMM) system to derive statistical shape models from radiographs: application to the accurate capture and global representation of proximal femur shape. *Osteoarthr Cartil* 2013;21:1537–44, <https://doi.org/10.1016/j.joca.2013.08.008>.
 14. Moher D, Liberati A, Tetzlaff J, Altman DG. Preferred reporting items for systematic reviews and meta-analyses: the PRISMA statement. *BMJ* 2009;339:b2535, <https://doi.org/10.1136/bmj.b2535>.
 15. Bramer WM, de Jonge GB, Rethlefsen ML, Mast F, Kleijnen J. A systematic approach to searching: an efficient and complete method to develop literature searches. *J Med Libr Assoc* 2018;106:531–41, <https://doi.org/10.5195/jmla.2018.283>.
 16. Bramer WM, Giustini D, de Jonge GB, Holland L, Bekhuis T. De-duplication of database search results for systematic reviews in EndNote. *J Med Libr Assoc* 2016;104:240–3, <https://doi.org/10.3163/1536-5050.104.3.014>.
 17. Bramer WM, Milic J, Mast F. Reviewing retrieved references for inclusion in systematic reviews using EndNote. *J Med Libr Assoc* 2017;105:84–7, <https://doi.org/10.5195/jmla.2017.111>.
 18. Wells GA, Shea B, O'Connell D, Peterson J, Welch V, Losos M, et al. The Newcastle-Ottawa Scale (NOS) for assessing the quality of nonrandomised studies in meta-analyses 2011. Available from: http://www.ohri.ca/programs/clinical_epidemiology/oxford.asp. Accessed November 20, 2019.
 19. Gregory JS, Waarsing JH, Day J, Pols HA, Reijman M, Weinans H, et al. Early identification of radiographic osteoarthritis of the hip using an active shape model to quantify changes in bone morphometric features: can hip shape tell us anything about the progression of osteoarthritis? *Arthritis Rheum* 2007;56:3634–43, <https://doi.org/10.1002/art.22982>.
 20. Agricola R, Leyland KM, Bierma-Zeinstra SMA, Thomas GE, Emans PJ, Spector TD, et al. Validation of statistical shape modelling to predict hip osteoarthritis in females: data from two prospective cohort studies (Cohort Hip and Cohort Knee and Chingford). *Rheumatology* 2015;54:2033–41, <https://doi.org/10.1093/rheumatology/kev232>.
 21. Nelson AE, Liu F, Lynch JA, Renner JB, Schwartz TA, Lane NE, et al. Association of incident symptomatic hip osteoarthritis with differences in hip shape by active shape modeling: the johnston county osteoarthritis project. *Arthritis Care Res* 2014;66:74–81, <https://doi.org/10.1002/acr.22094>.
 22. Barr RJ, Gregory JS, Reid DM, Aspden RM, Yoshida K, Hosie G, et al. Predicting OA progression to total hip replacement: can we do better than risk factors alone using active shape modelling as an imaging biomarker? *Rheumatology (UK)* 2012;51:562–70, <https://doi.org/10.1093/rheumatology/ker382>.
 23. Ahedi HG, Aspden RM, Blizzard LC, Saunders FR, Cicuttini FM, Aitken DA, et al. Hip shape as a predictor of osteoarthritis progression in a prospective population cohort. *Arthritis Care Res* 2017;69:1566–73, <https://doi.org/10.1002/acr.23166>.
 24. Castaño-Betancourt MC, Van Meurs JBJ, Bierma-Zeinstra S, Rivadeneira F, Hofman A, Weinans H, et al. The contribution of hip geometry to the prediction of hip osteoarthritis. *Osteoarthr Cartil* 2013;21:1530–6, <https://doi.org/10.1016/j.joca.2013.06.012>.
 25. Agricola R, Reijman M, Bierma-Zeinstra SMA, Verhaar JAN, Weinans H, Waarsing JH. Total hip replacement but not clinical osteoarthritis can be predicted by the shape of the hip: a prospective cohort study (CHECK). *Osteoarthr Cartil* 2013;21:559–64, <https://doi.org/10.1016/j.joca.2013.01.005>.
 26. Lynch JA, Parimi N, Chaganti RK, Nevitt MC, Lane NE. The association of proximal femoral shape and incident radiographic hip OA in elderly women. *Osteoarthr Cartil* 2009;17:1313–8, <https://doi.org/10.1016/j.joca.2009.04.011>.
 27. Mezhev V, Laslett LL, Ahedi H, Blizzard CL, Aspden RM, Gregory JS, et al. Predictors of total hip replacement in community based older adults: a cohort study (Abstract). *Osteoarthr Cartil* 2019;27:S79–80, <https://doi.org/10.1016/j.joca.2019.02.112>.
 28. Agricola R, Heijboer MP, Bierma-Zeinstra SMA, Verhaar JAN, Weinans H, Waarsing JH. Cam impingement causes osteoarthritis of the hip: a nationwide prospective cohort study (CHECK). *Ann Rheum Dis* 2013;72:918–23, <https://doi.org/10.1136/annrheumdis-2012-201643>.
 29. Agricola R, Waarsing JH, Arden NK, Carr AJ, Bierma-Zeinstra SMA, Thomas GE, et al. Cam impingement of the hip—a risk factor for hip osteoarthritis. *Nat Rev Rheumatol* 2013;9:630–4, <https://doi.org/10.1038/nrrheum.2013.114>.
 30. Kemp JL, Crossley KM, Agricola R, Geuskens F, van Middelkoop M. Radiographic hip osteoarthritis is prevalent, and is related to cam deformity 12–24 Months post-hip arthroscopy. *Int J Sports Phys Ther* 2018;13:177–84, <https://doi.org/10.26603/ijsp20180177>.
 31. Harris-Hayes M, Royer NK. Relationship of acetabular dysplasia and femoroacetabular impingement to hip osteoarthritis: a focused review. *PM R* 2011;3:1055–67, <https://doi.org/10.1016/j.pmrj.2011.08.533>. e1051.
 32. McWilliams DF, Doherty SA, Jenkins WD, Maciewicz RA, Muir KR, Zhang W, et al. Mild acetabular dysplasia and risk of osteoarthritis of the hip: a case-control study. *Ann Rheum Dis* 2010;69:1774–8, <https://doi.org/10.1136/ard.2009.127076>.
 33. Lievens AM, Bierma-Zeinstra SMA, Verhagen AP, Verhaar JAN, Koes BW. Influence of hip dysplasia on the development of osteoarthritis of the hip. *Ann Rheum Dis* 2004;63:621–6, <https://doi.org/10.1136/ard.2003.009860>.
 34. Lane NE, Lin P, Christiansen L, Gore LR, Williams EN, Hochberg MC, et al. Association of mild acetabular dysplasia with an increased risk of incident hip osteoarthritis in elderly white women: the study of osteoporotic fractures. *Arthritis Rheum* 2000;43:400–4, [https://doi.org/10.1002/1529-0131\(200002\)43:2<400::Aid-anr21>3.0.Co;2-d](https://doi.org/10.1002/1529-0131(200002)43:2<400::Aid-anr21>3.0.Co;2-d).
 35. Reijman M, Hazes JMW, Pols HAP, Koes BW, Bierma-Zeinstra SMA. Acetabular dysplasia predicts incident

- osteoarthritis of the hip: the Rotterdam study. *Arthritis Rheum* 2005;52:787–93, <https://doi.org/10.1002/art.20886>.
36. Faber BG, Baird D, Gregson CL, Gregory JS, Barr RJ, Aspden RM, et al. DXA-derived hip shape is related to osteoarthritis: findings from in the MrOS cohort. *Osteoarthr Cartil* 2017;25:2031–8, <https://doi.org/10.1016/j.joca.2017.09.006>.
 37. Faber BG, Bredbenner TL, Baird D, Gregory J, Saunders F, Giuraniuc CV, et al. Subregional statistical shape modelling identifies lesser trochanter size as a possible risk factor for radiographic hip osteoarthritis, a cross-sectional analysis from the Osteoporotic Fractures in Men Study. *Osteoarthr Cartil* 2020, <https://doi.org/10.1016/j.joca.2020.04.011>.
 38. Giori NJ, Trousdale RT. Acetabular retroversion is associated with osteoarthritis of the hip. *Clin Orthop Relat Res* 2003;263–9, <https://doi.org/10.1097/01.blo.0000093014.90435.64>.
 39. Kim WY, Hutchinson CE, Andrew JG, Allen PD. The relationship between acetabular retroversion and osteoarthritis of the hip. *J Bone Jt Surg Ser B* 2006;88:727–9, <https://doi.org/10.1302/0301-620x.88b6.17430>.
 40. Tönnis D, Heinecke A. Acetabular and femoral anteversion: relationship with osteoarthritis of the hip. *J Bone Jt Surg Ser A* 1999;81:1747–70, <https://doi.org/10.2106/00004623-199912000-00014>.
 41. Waarsing JH, Kloppenburg M, Slagboom PE, Kroon HM, Houwing-Duistermaat JJ, Weinans H, et al. Osteoarthritis susceptibility genes influence the association between hip morphology and osteoarthritis. *Arthritis Rheum* 2011;63:1349–54, <https://doi.org/10.1002/art.30288>.
 42. Ida T, Nakamura Y, Hagio T, Naito M. Prevalence and characteristics of cam-type femoroacetabular deformity in 100 hips with symptomatic acetabular dysplasia: a case control study. *J Orthop Surg Res* 2014;9:93, <https://doi.org/10.1186/s13018-014-0093-4>.
 43. Clohisy JC, Nunley RM, Carlisle JC, Schoenecker PL. Incidence and characteristics of femoral deformities in the dysplastic hip. *Clin Orthop Relat Res* 2009;467:128–34, <https://doi.org/10.1007/s11999-008-0481-3>.
 44. Kobayashi N, Inaba Y, Kubota S, Nakamura S, Tezuka T, Yukizawa Y, et al. The distribution of impingement region in cam-type femoroacetabular impingement and borderline dysplasia of the hip with or without cam deformity: a computer simulation study. *Arthroscopy* 2017;33:329–34, <https://doi.org/10.1016/j.arthro.2016.08.018>.
 45. Van Houcke J, Khanduja V, Pattyn C, Audenaert E. The history of biomechanics in total hip arthroplasty. *Indian J Orthop* 2017;51:359, https://doi.org/10.4103/ortho.IJOrtho_280_17.
 46. Barr RJ, Gregory JS, Yoshida K, Alesci S, Aspden RM, Reid DM. Significant morphological change in osteoarthritic hips identified over 6–12 months using statistical shape modelling. *Osteoarthr Cartil* 2018;26:783–9, <https://doi.org/10.1016/j.joca.2018.04.004>.